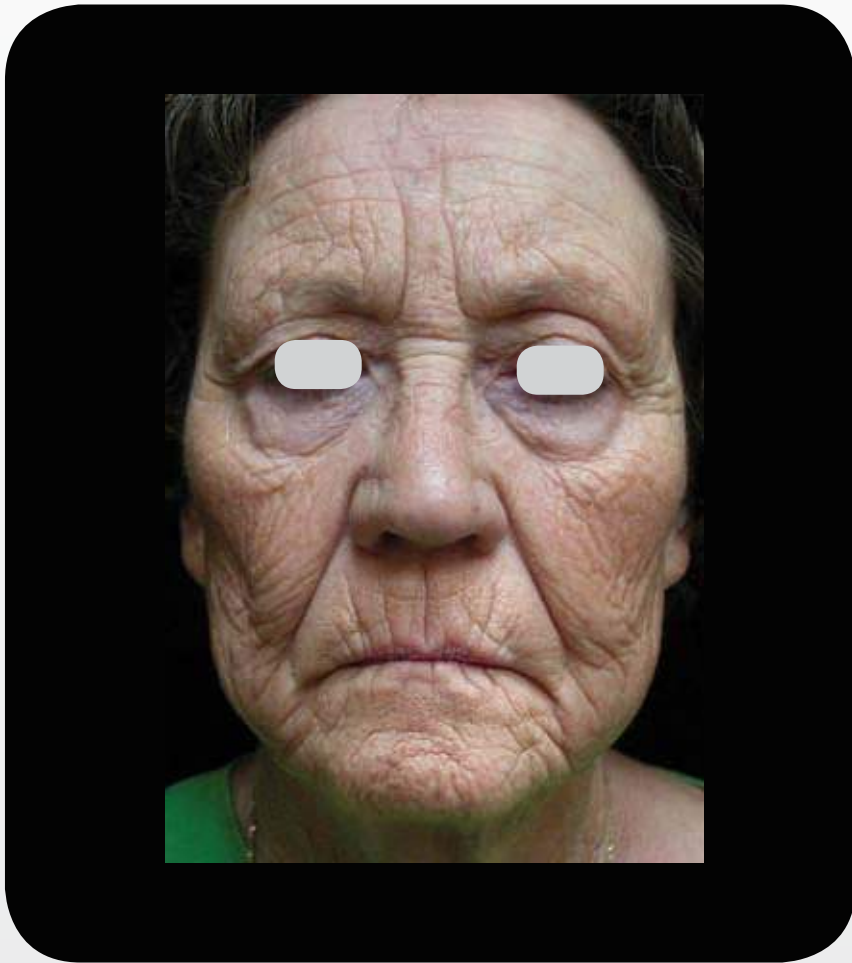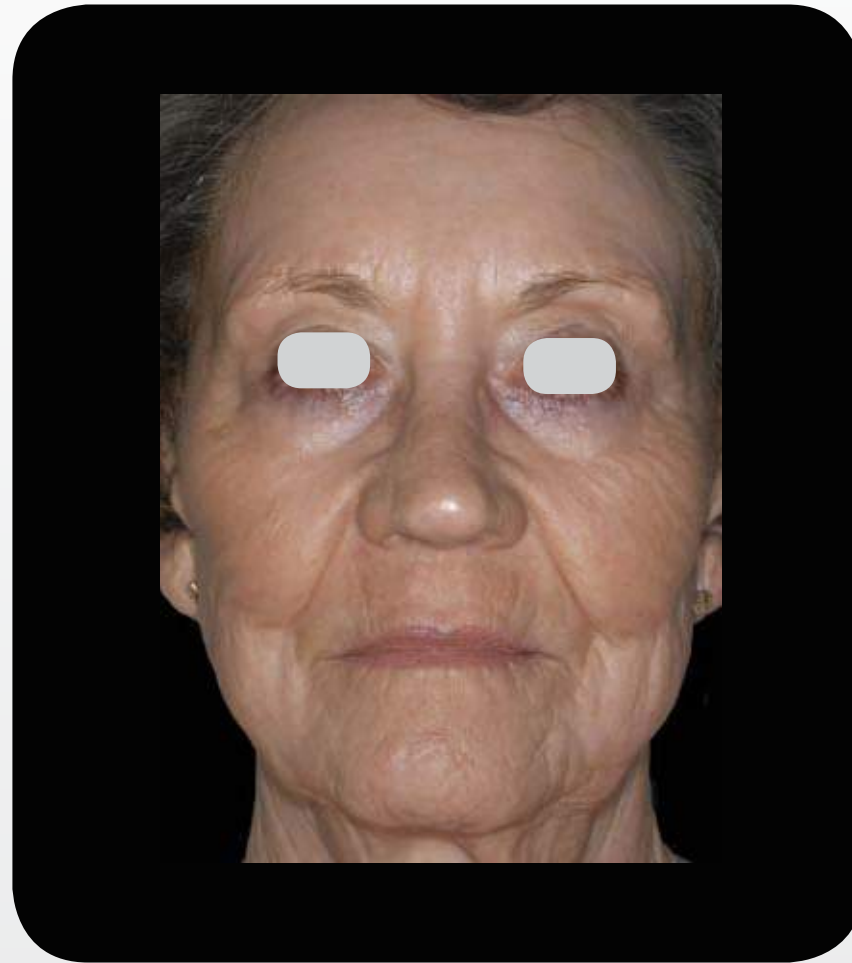


Deep Skin Resurfacing



Baseline

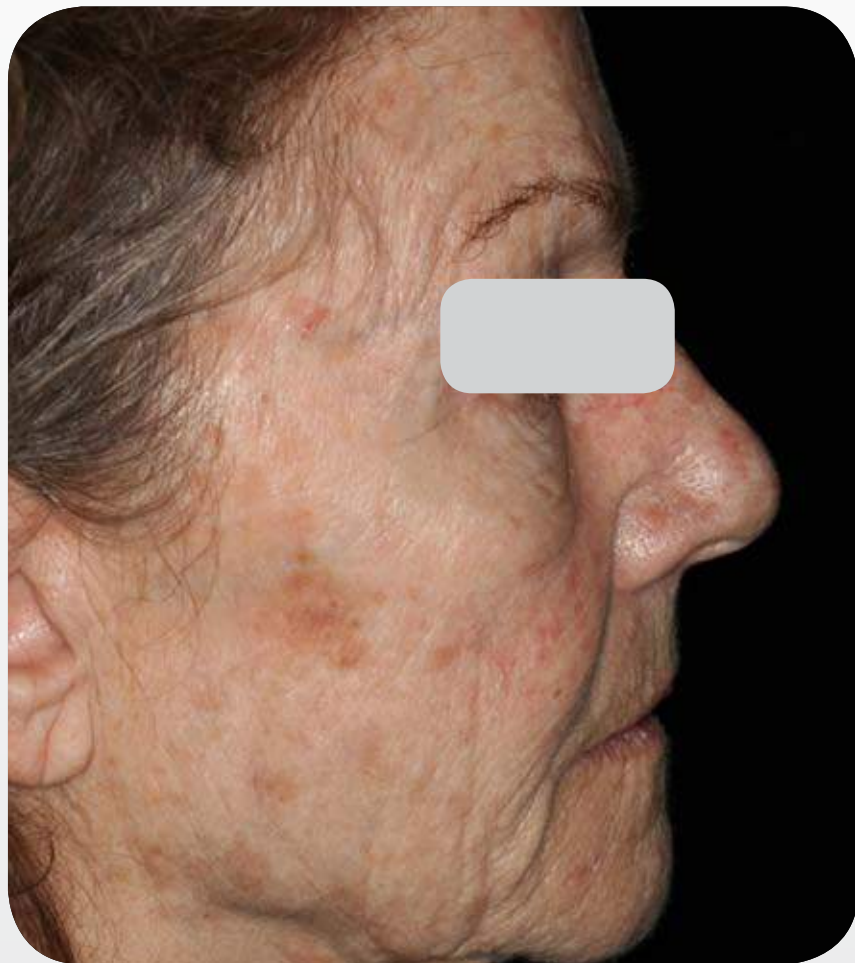

1 year after treatment

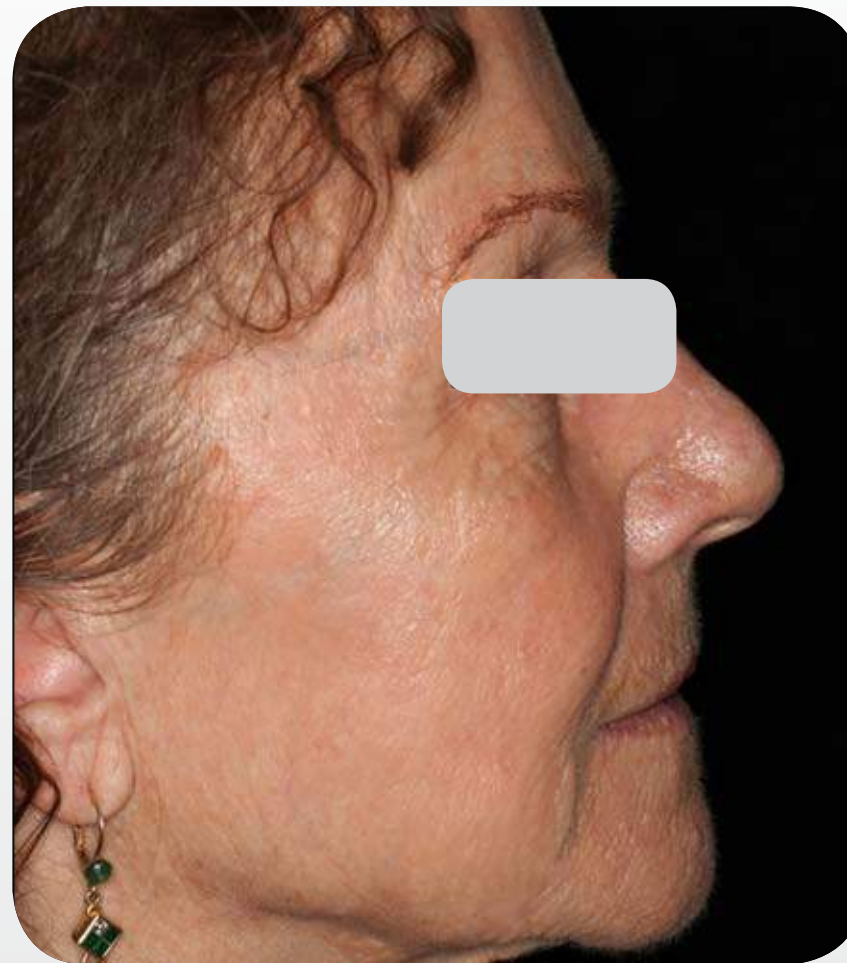Courtesy of Suzanne L. Kilmer, MD

PB-1003880 Rev C

Deep Skin Resurfacing



Baseline

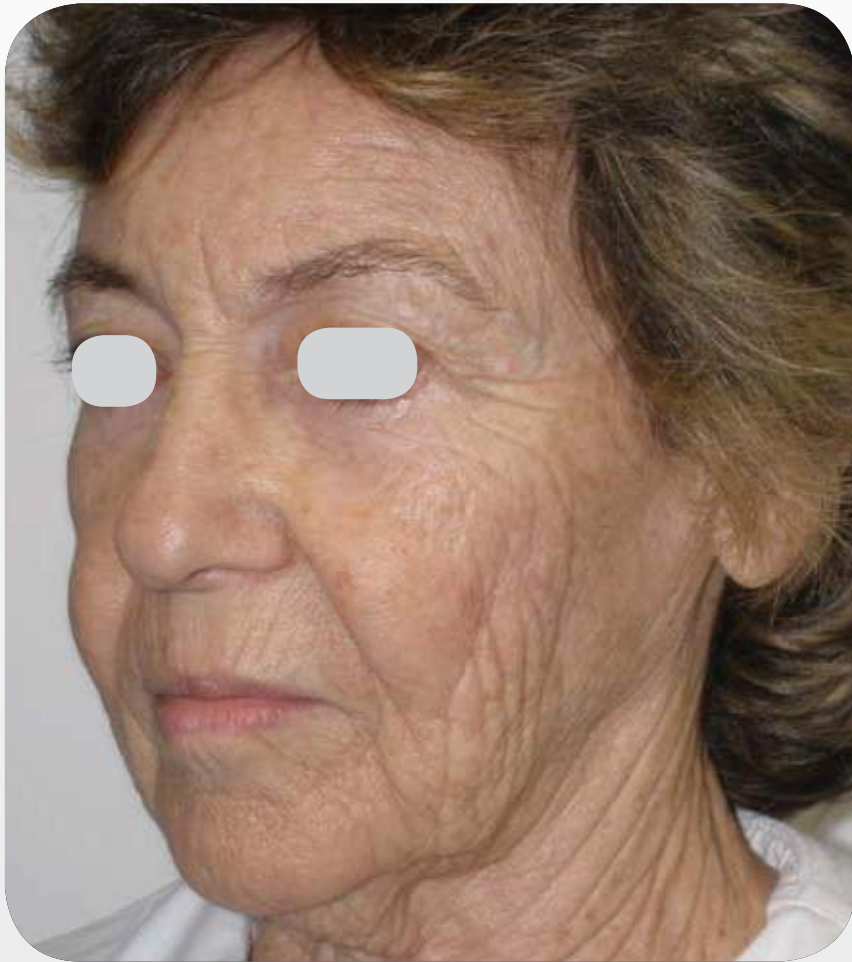


2 years after treatment

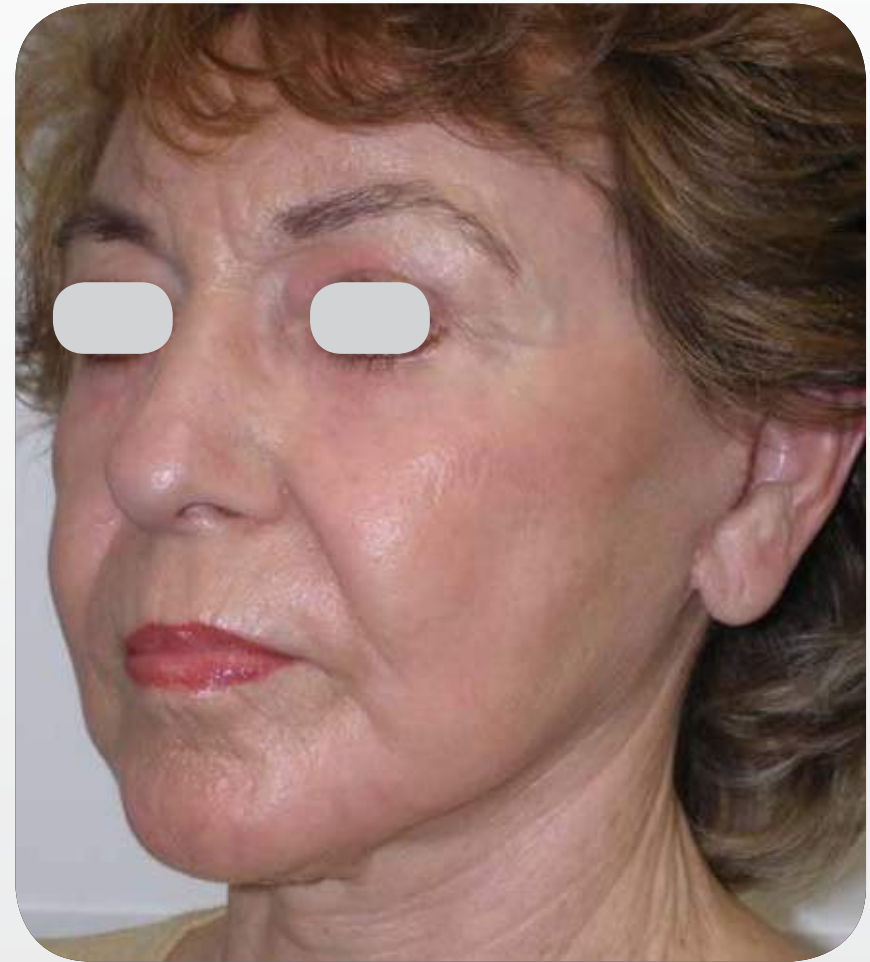
Courtesy of Matteo Tretti Clementoni, MD

PB-1003880 Rev C

Deep Skin Resurfacing



Baseline

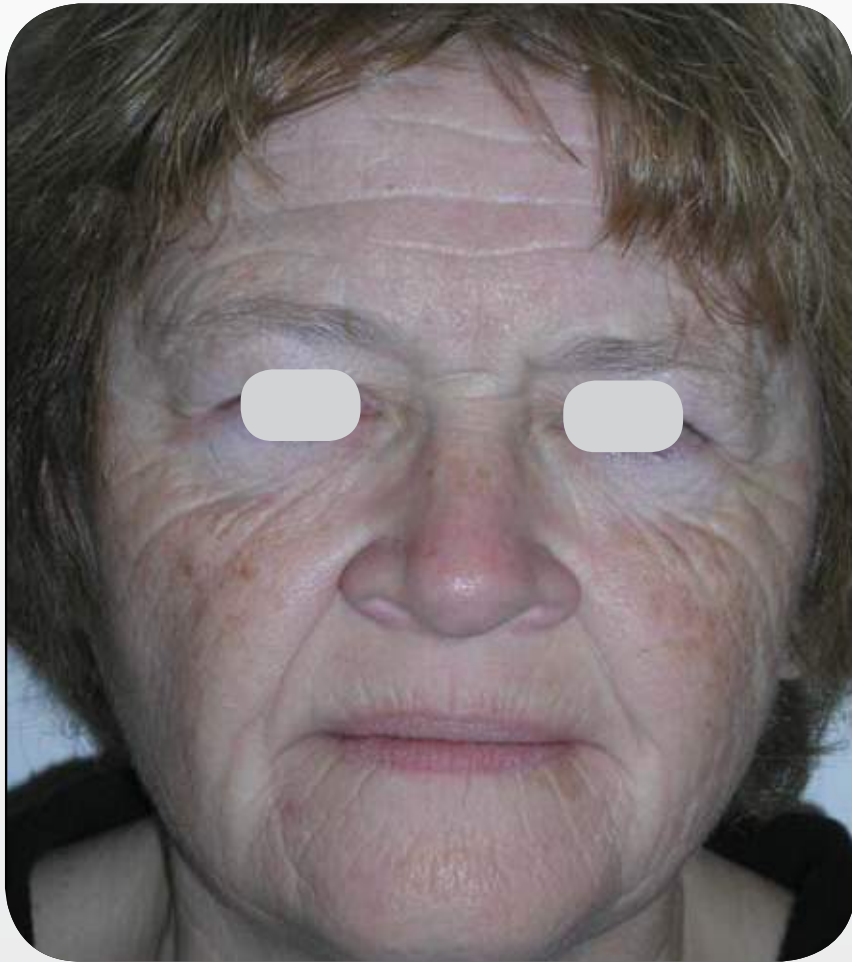


After treatment

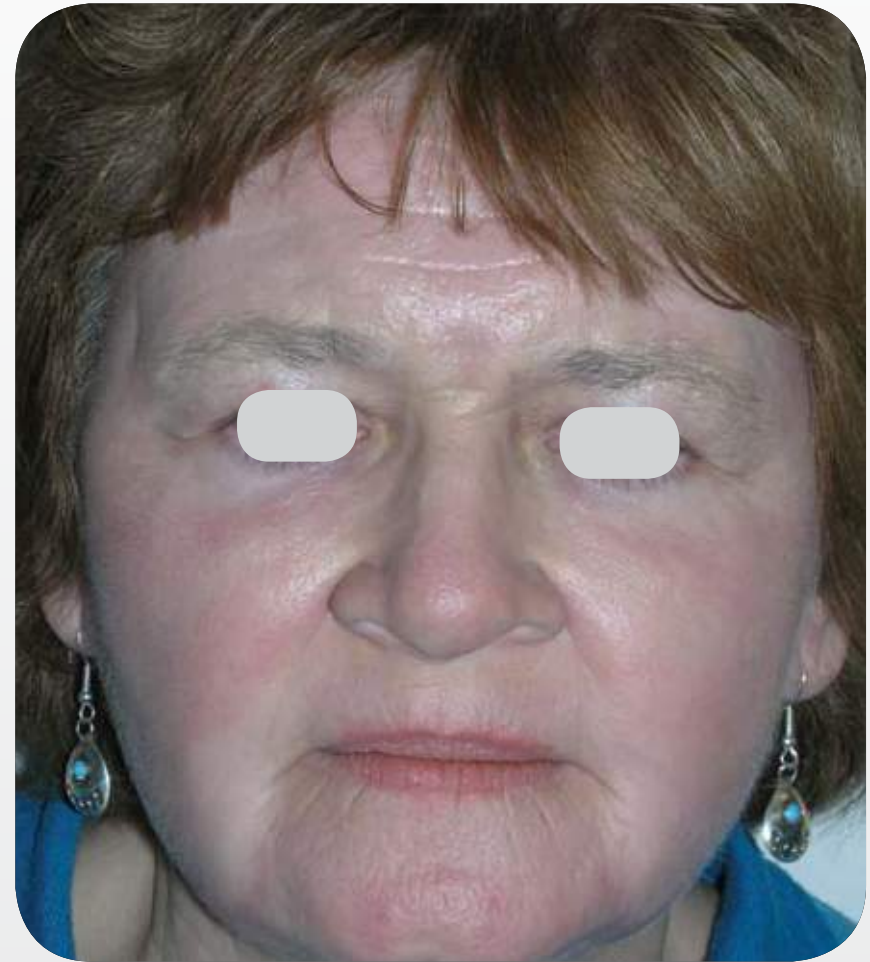
Courtesy of Joseph Niamtu III, DMD

PB-1003880 Rev C

Deep Skin Resurfacing



Baseline

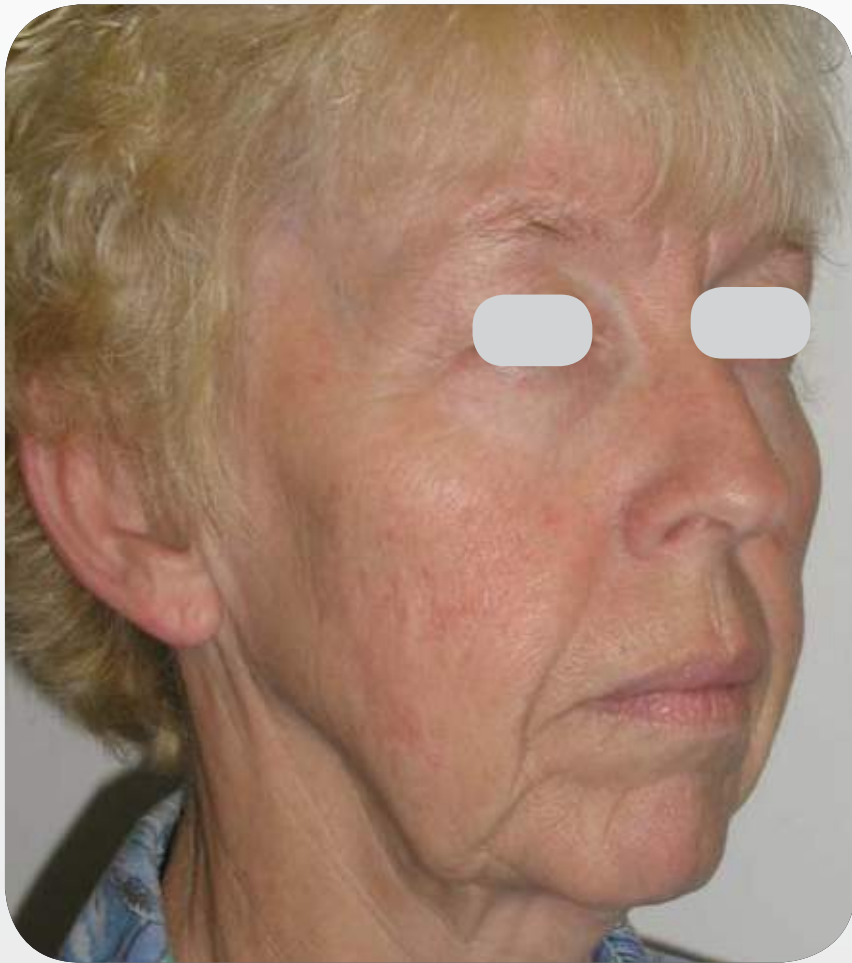


After treatment

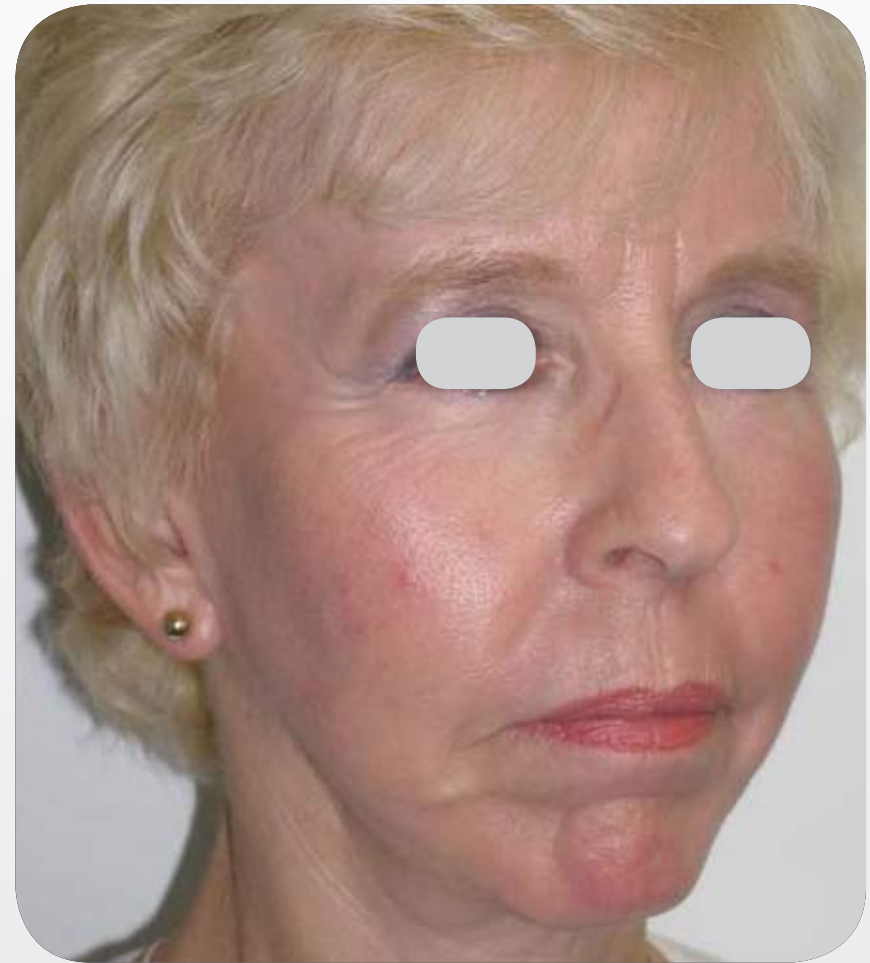Courtesy of Joseph Niamtu III, DMD

PB-1003880 Rev C

Deep Skin Resurfacing



Baseline

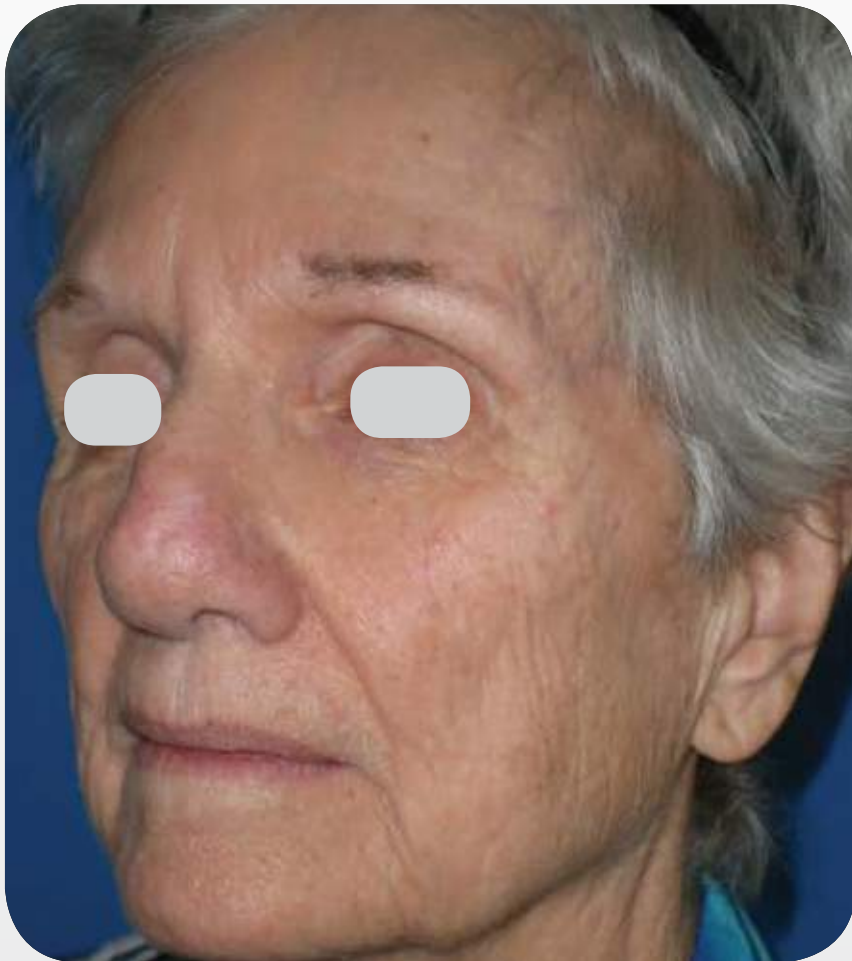


After treatment

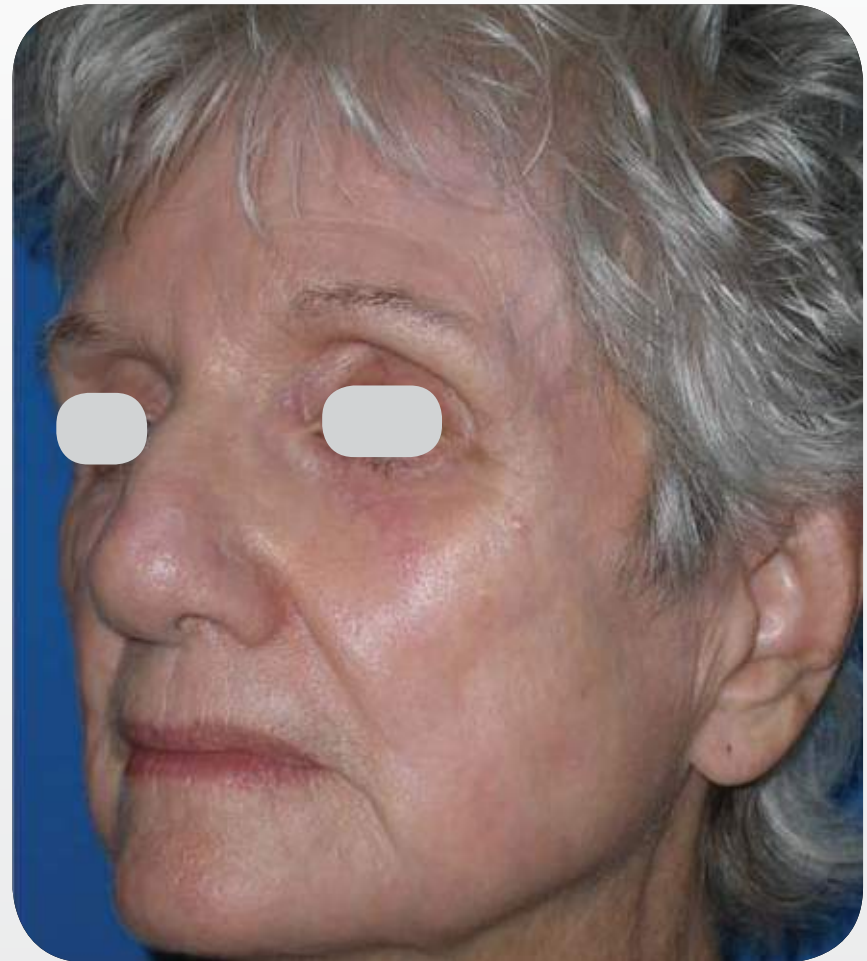
Courtesy of Joseph Niamtu III, DMD

PB-1003880 Rev C

Skin Resurfacing



Baseline

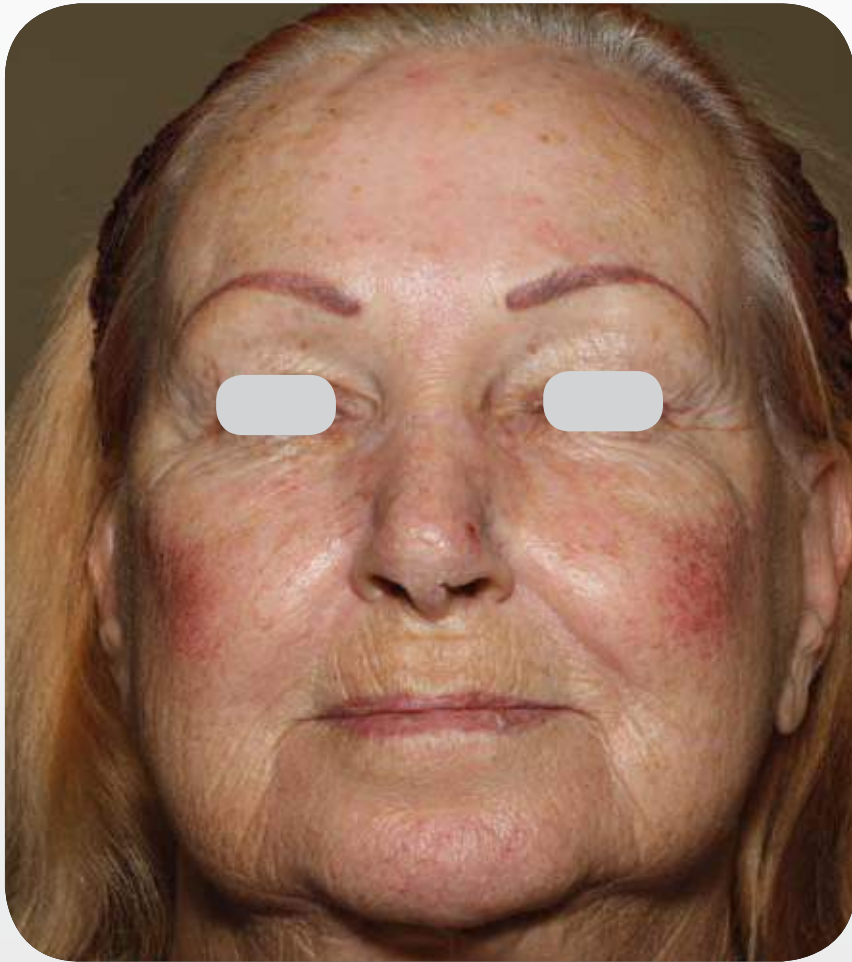

After treatment

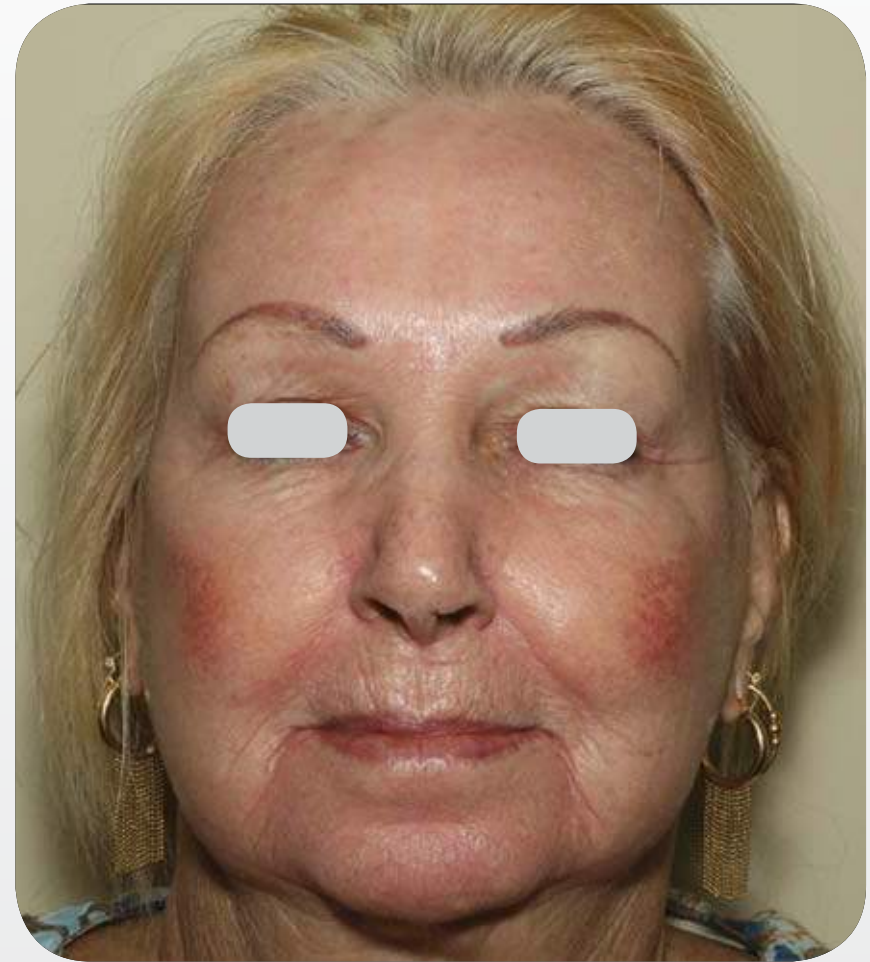Courtesy of Joseph Niamtu III, DMD

PB-1003880 Rev C

Skin Resurfacing



Baseline

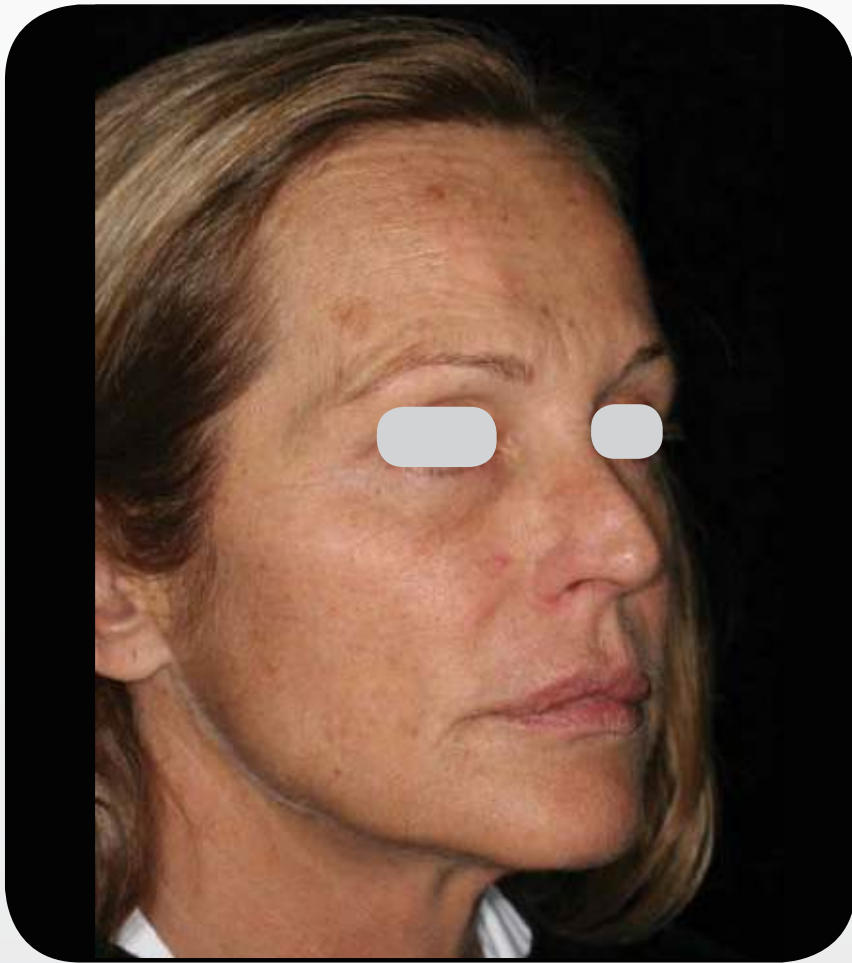


After treatment

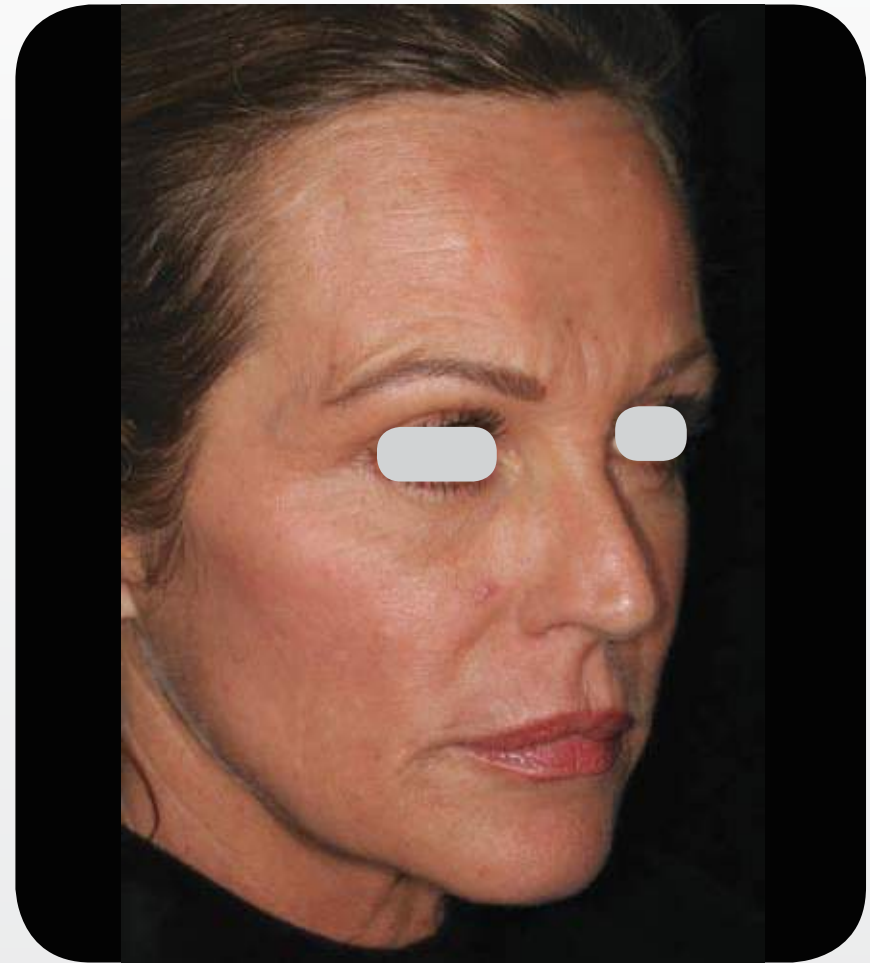Courtesy of Andrew Hector, MD

PB-1003880 Rev C

Skin Resurfacing



Baseline

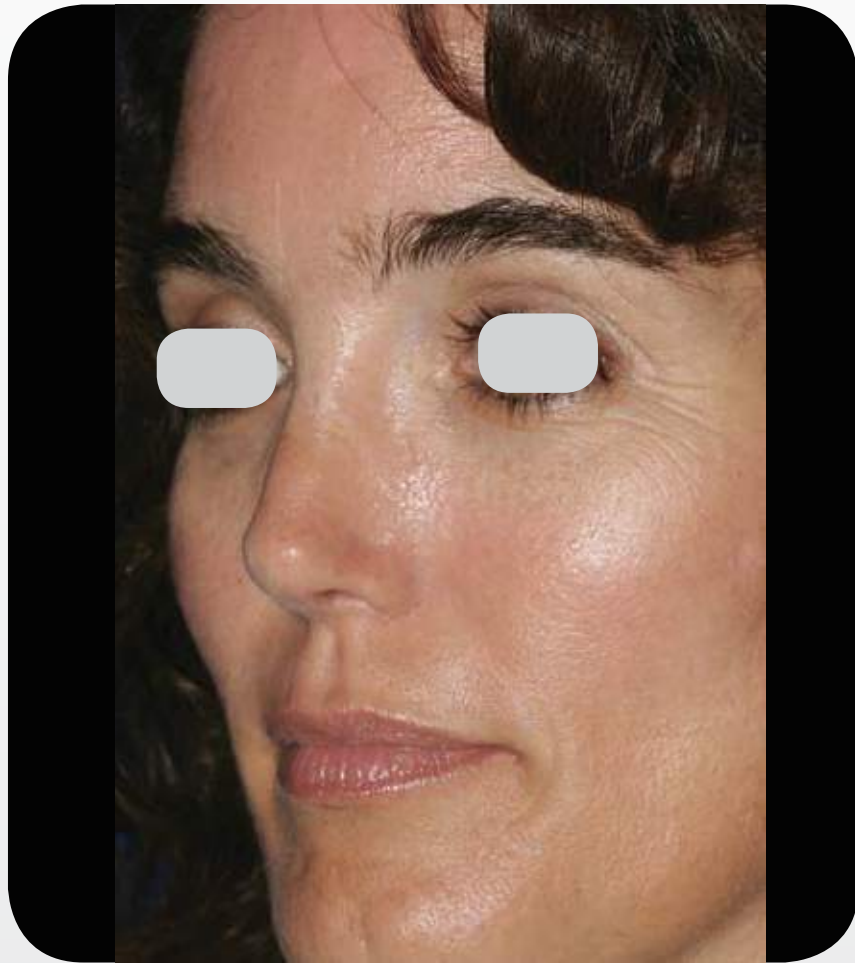

7 days after treatment

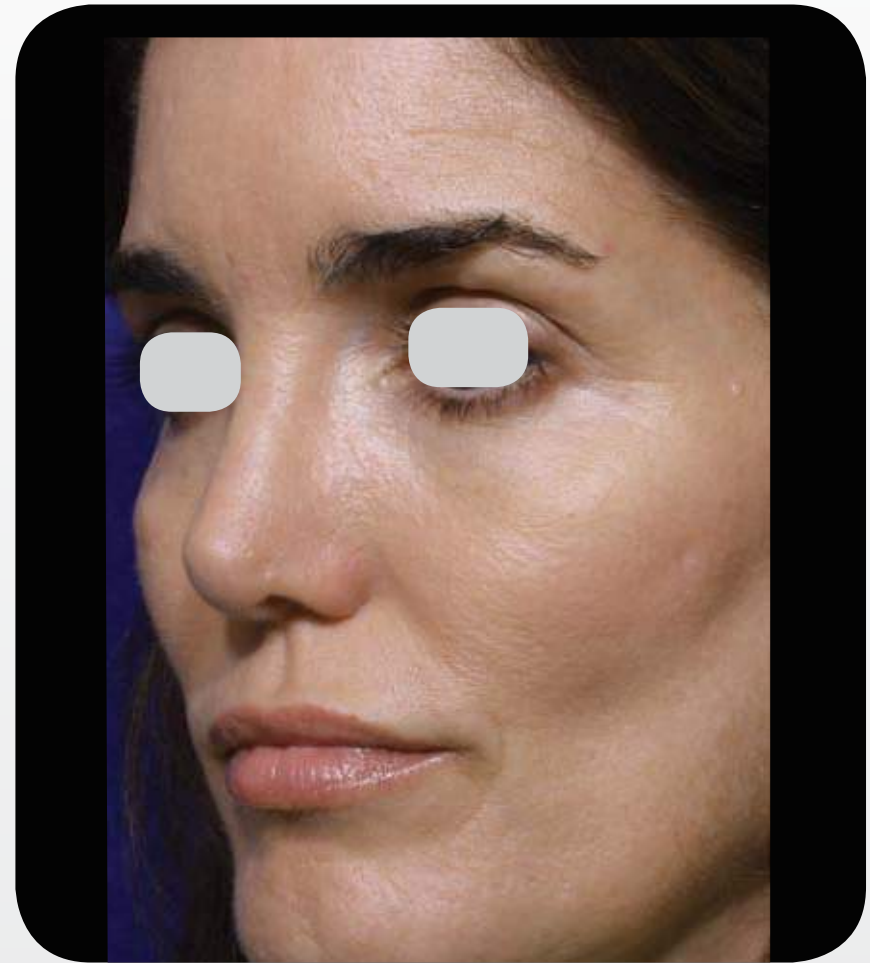Courtesy of Matteo Tretti Clementoni, MD

PB-1003880 Rev C

Skin Resurfacing

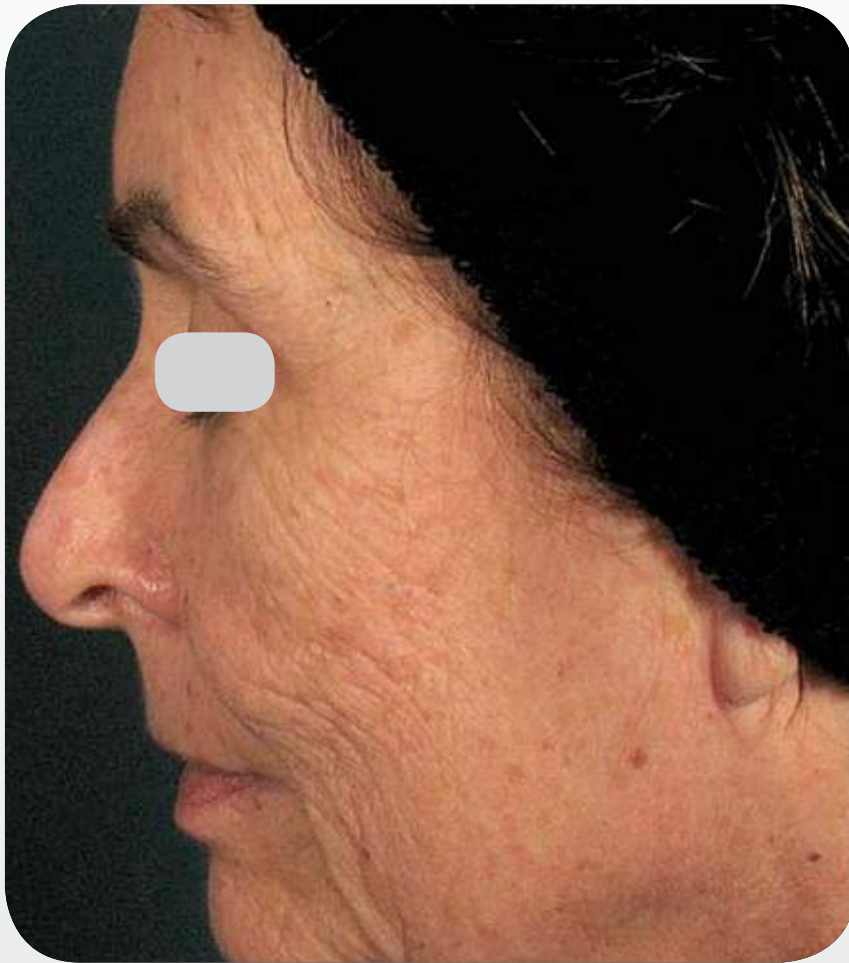

Baseline

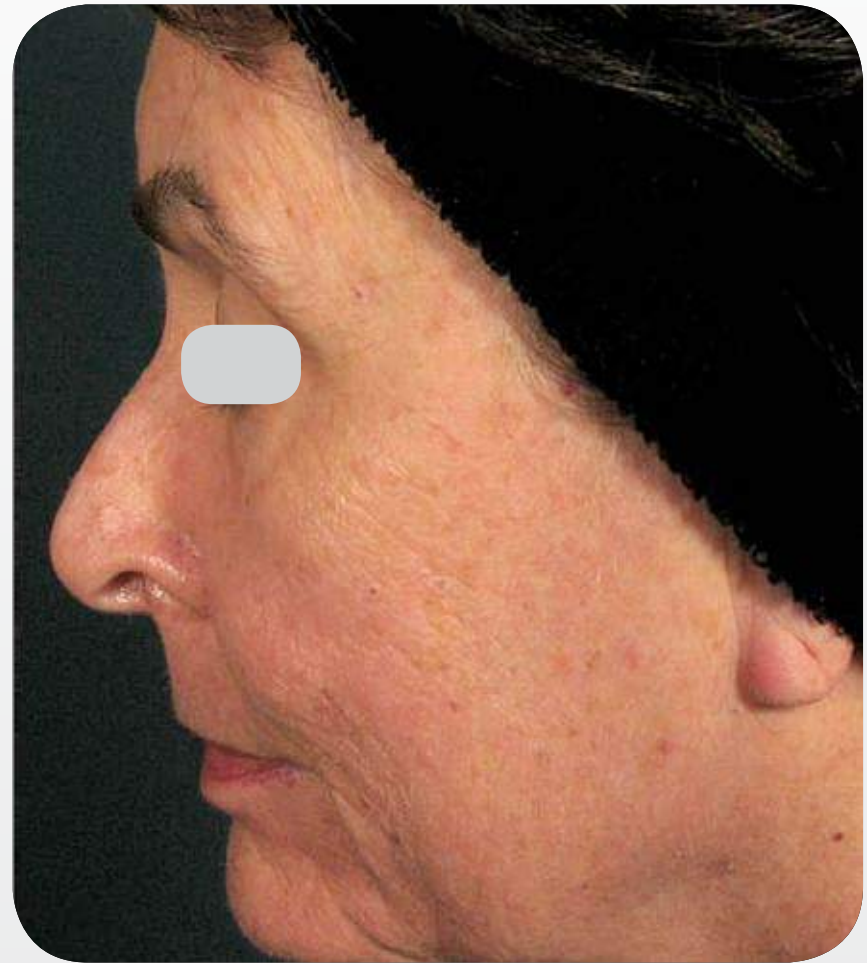

5 months after treatment

Skin Resurfacing

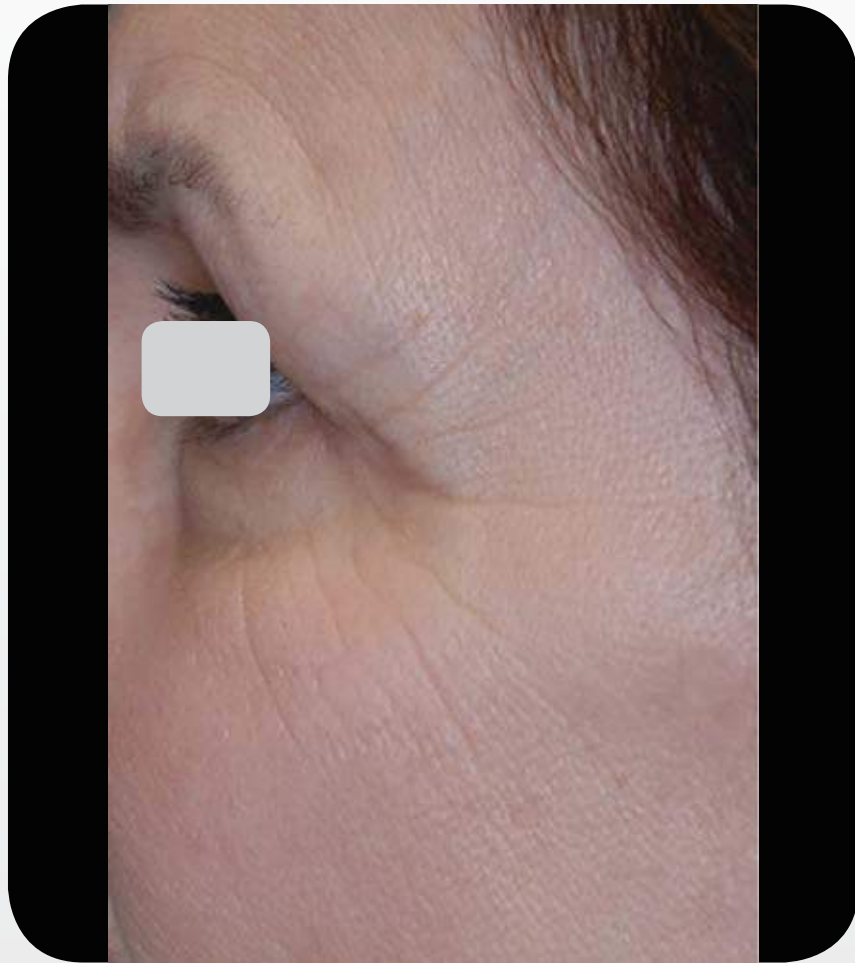


Baseline

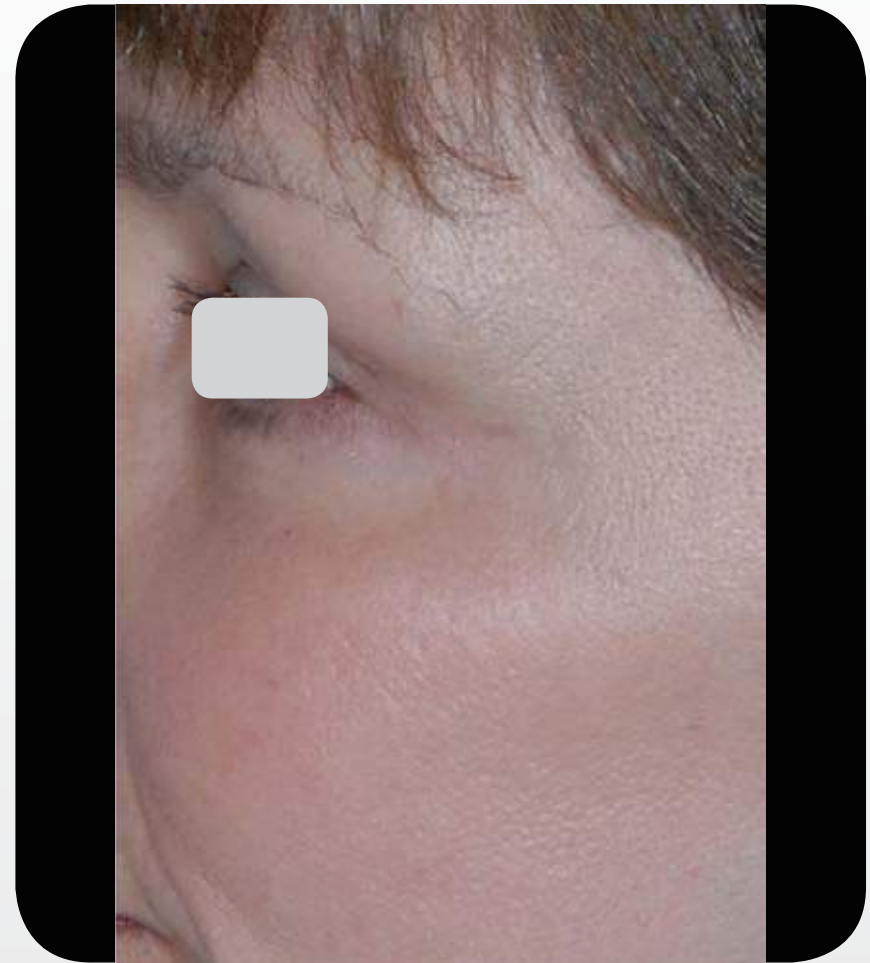

After treatment

Periorbital Skin Resurfacing



Baseline

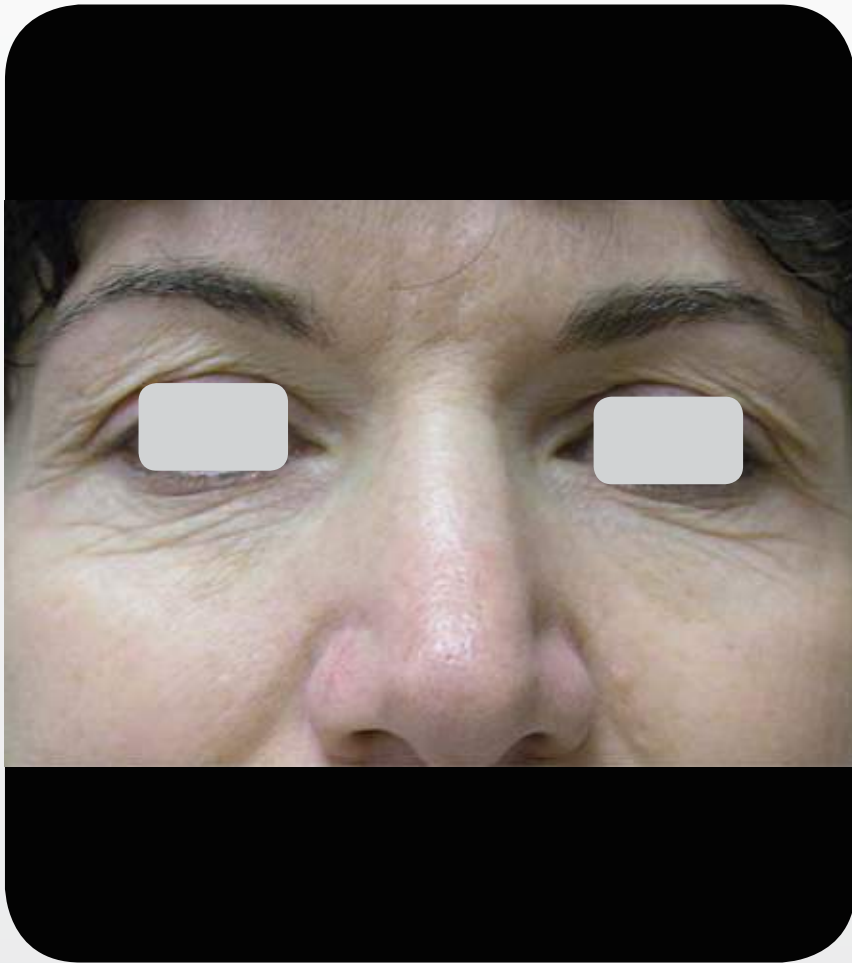

3 months after treatment

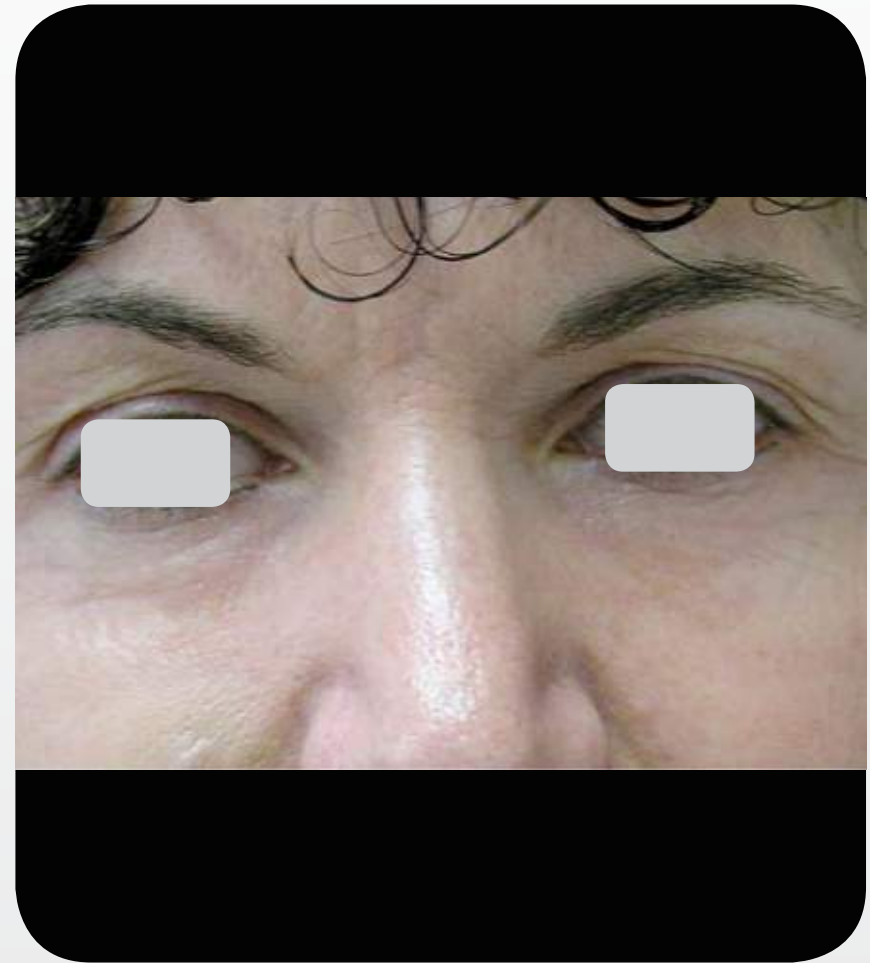Courtesy of J. Kevin Duplechain, MD

PB-1003880 Rev C

Periorbital Skin Resurfacing

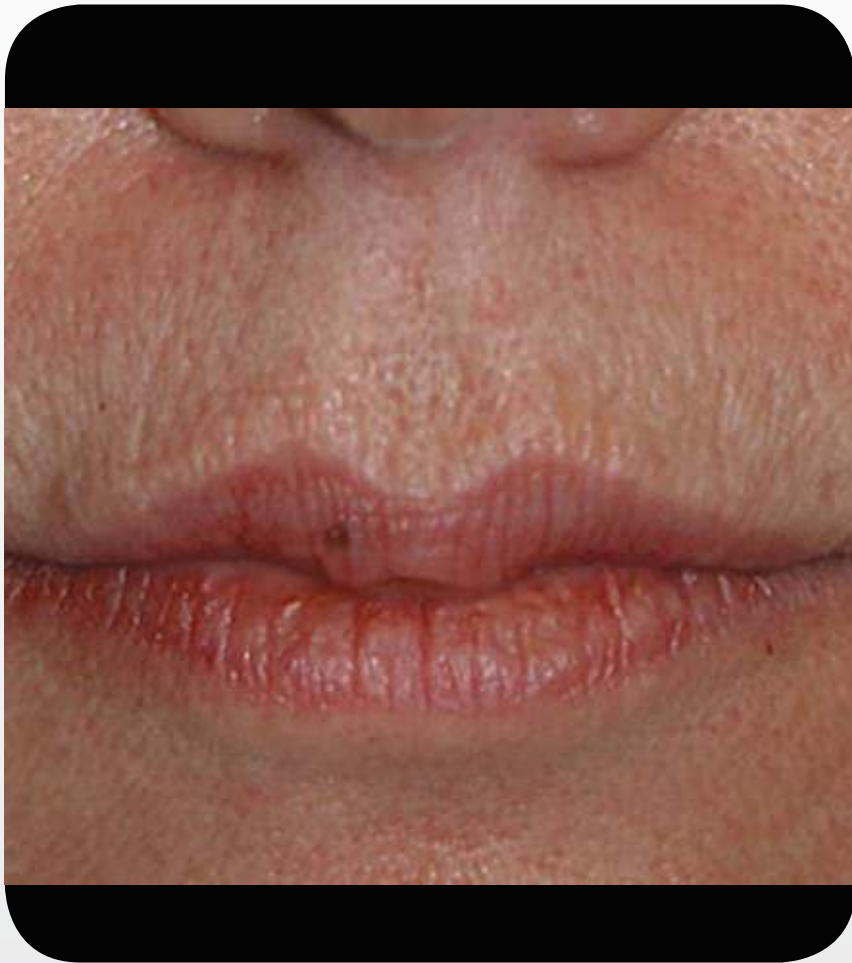

Baseline

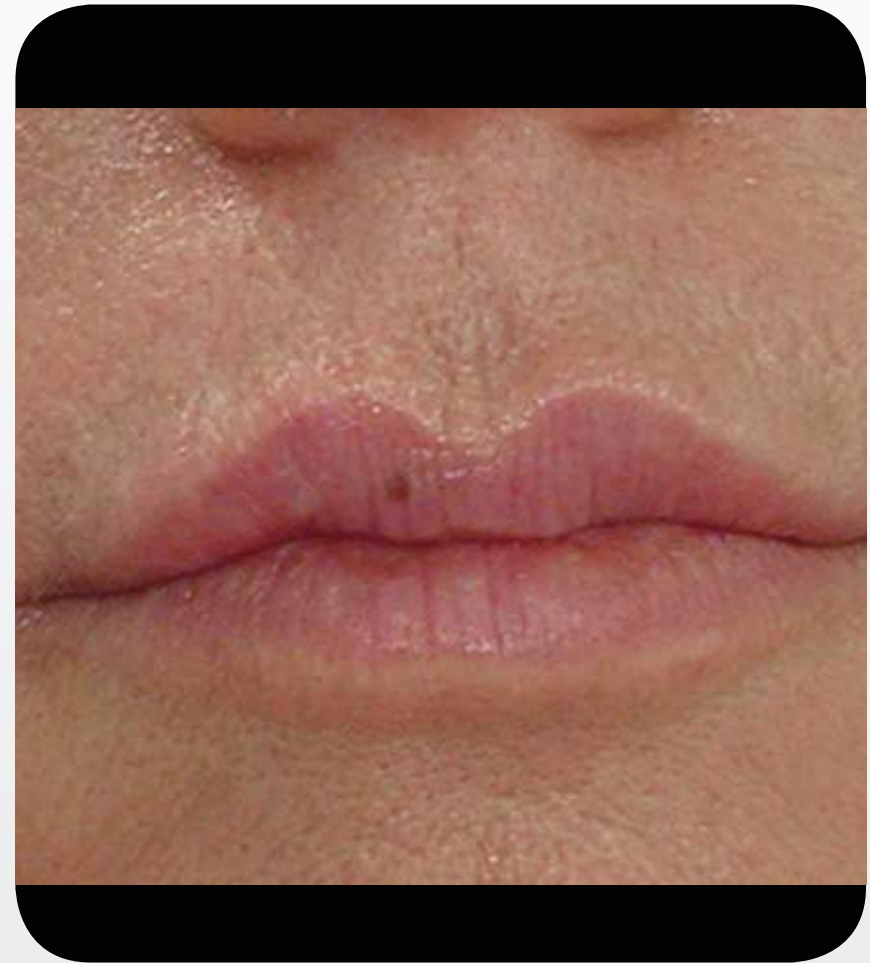

1 week after 1 treatment

Perioral Skin Resurfacing

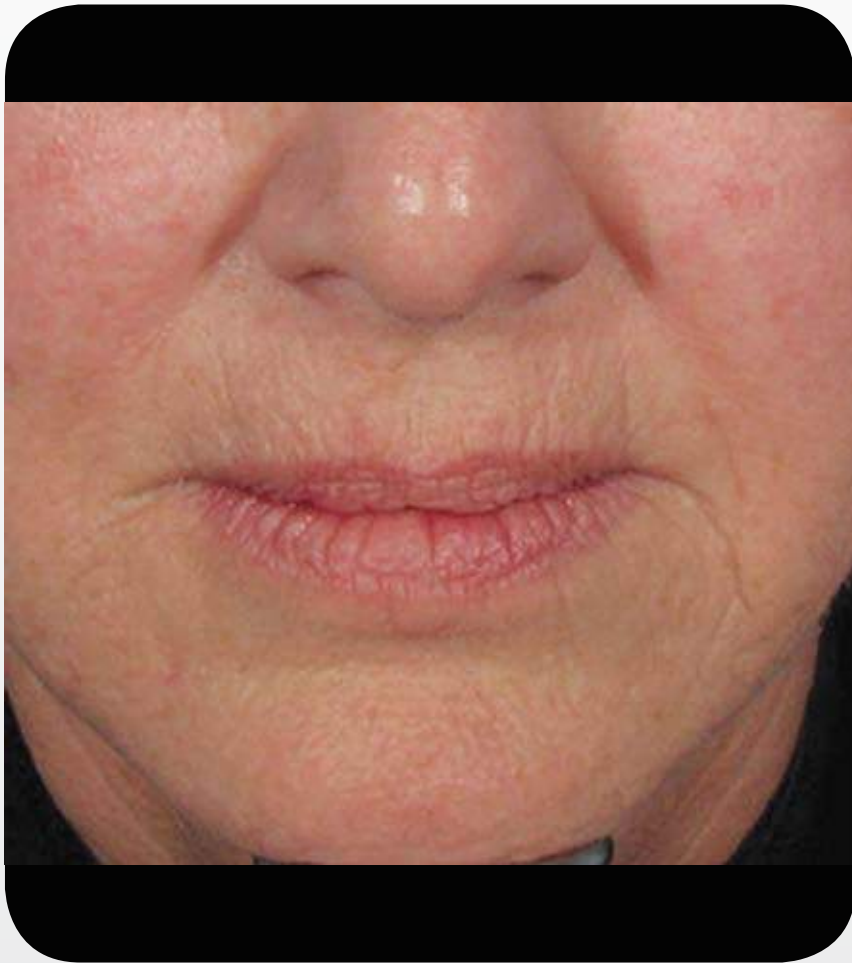

Baseline

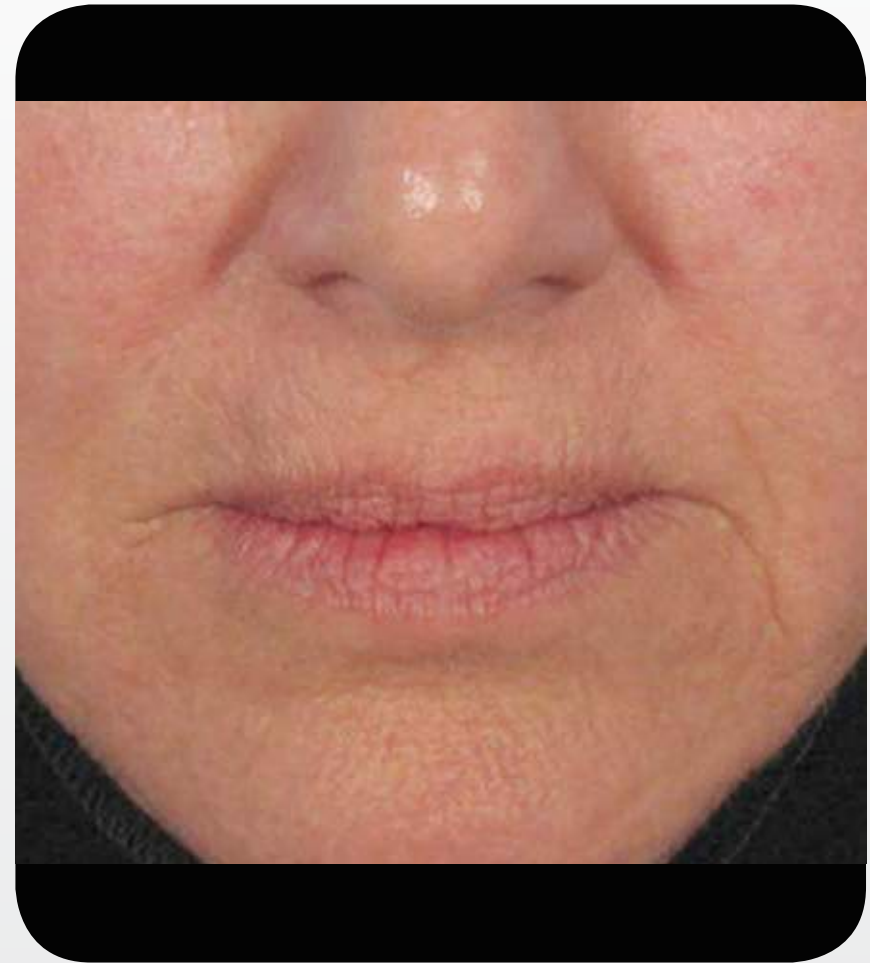

6 weeks after 1 treatment

Perioral Skin Resurfacing

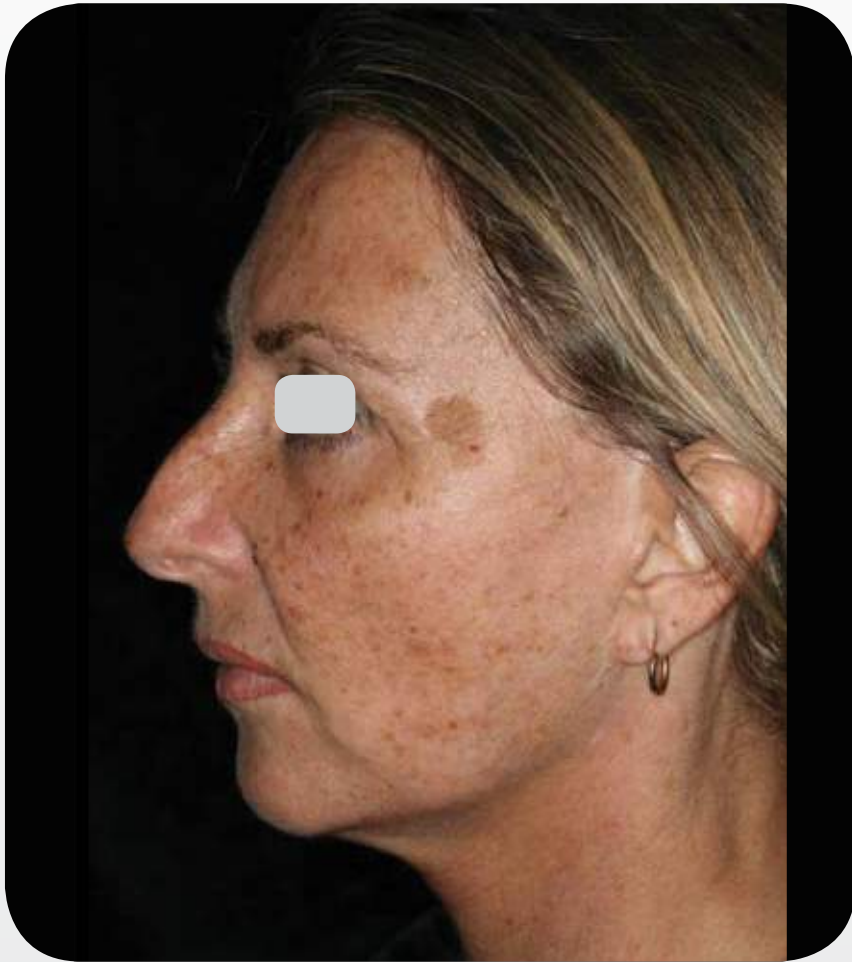

Baseline

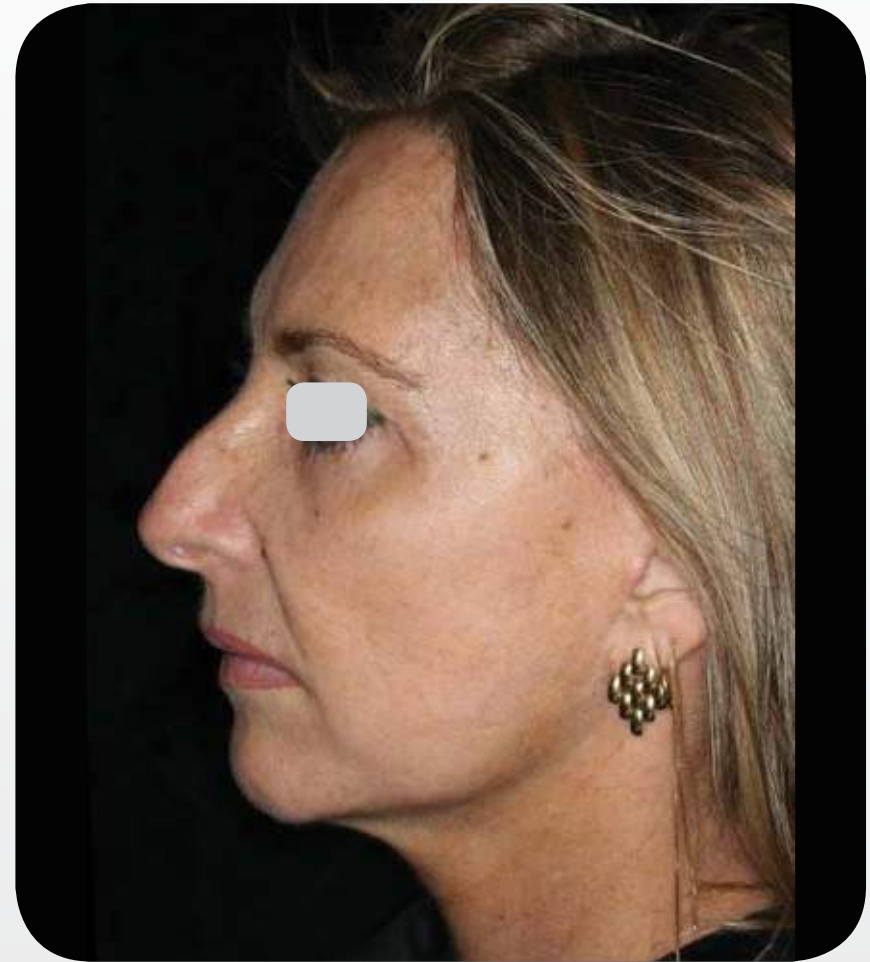

20 days after 1 treatment

Dyschromia



Baseline

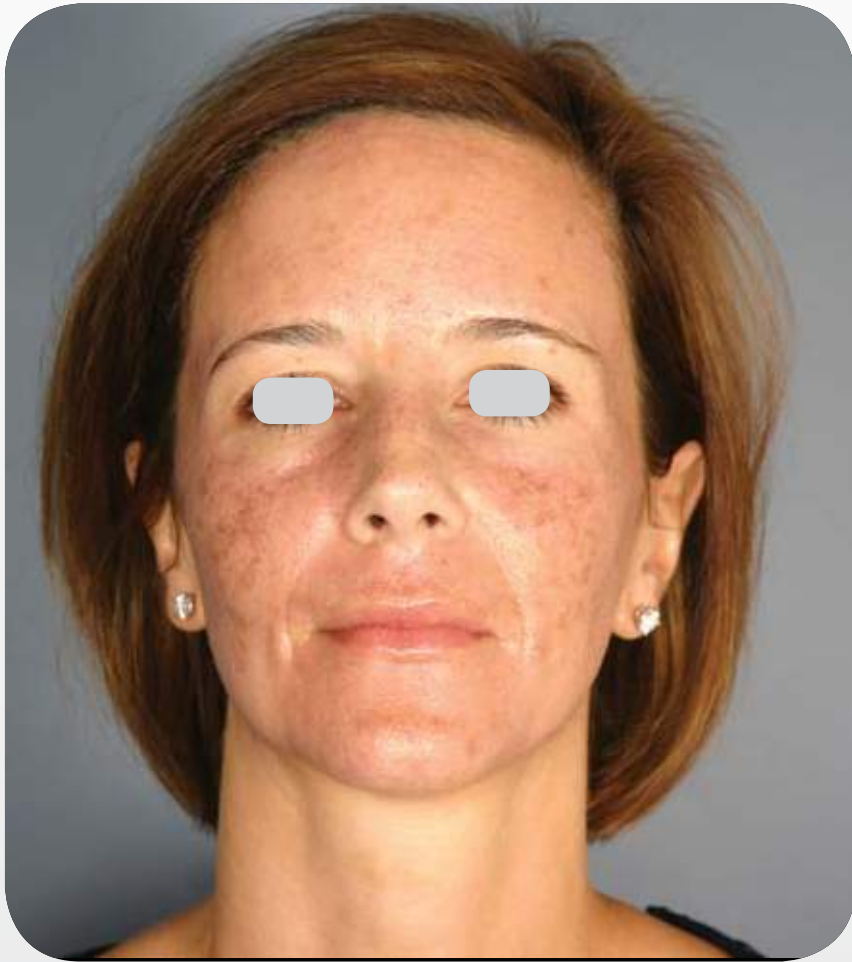

1 month after treatment

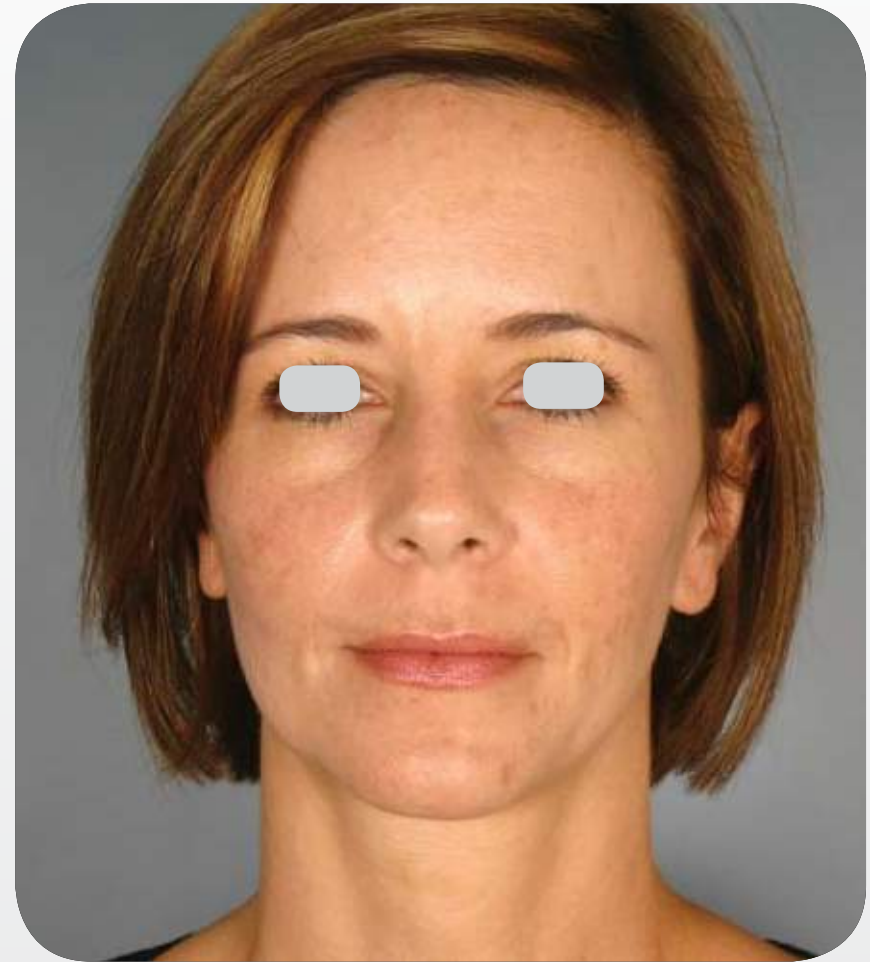
Courtesy of Matteo Tretti Clementoni, MD

PB-1003880 Rev C

Dyschromia



Baseline

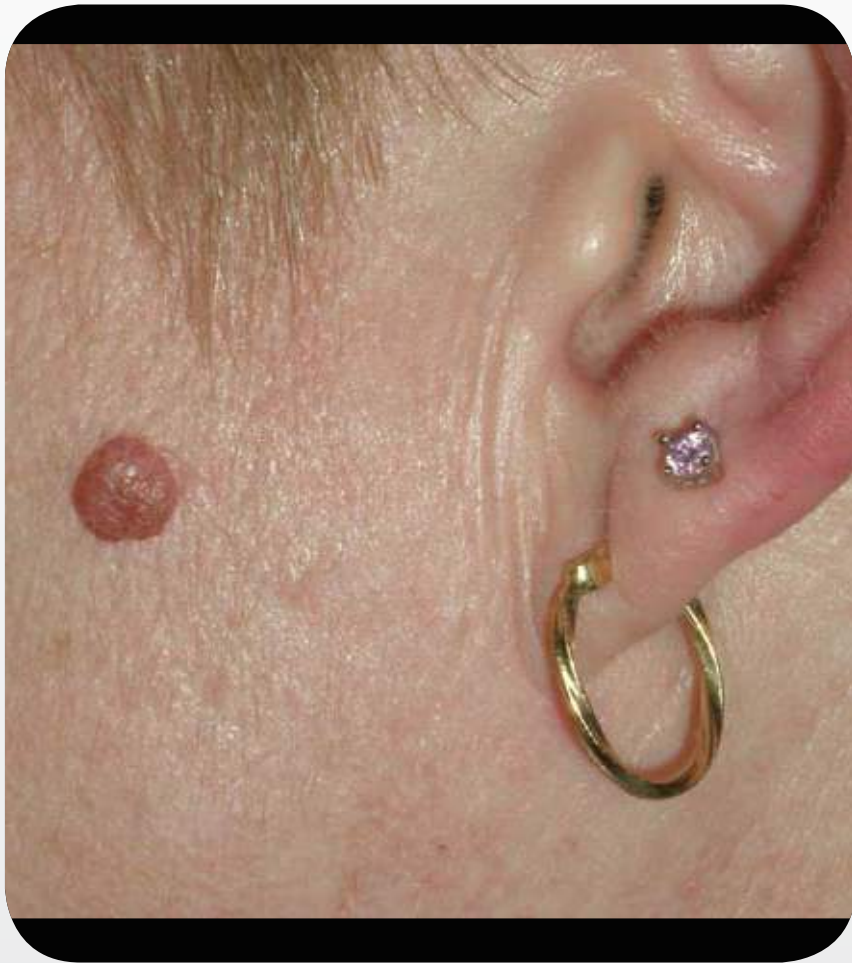

After treatment

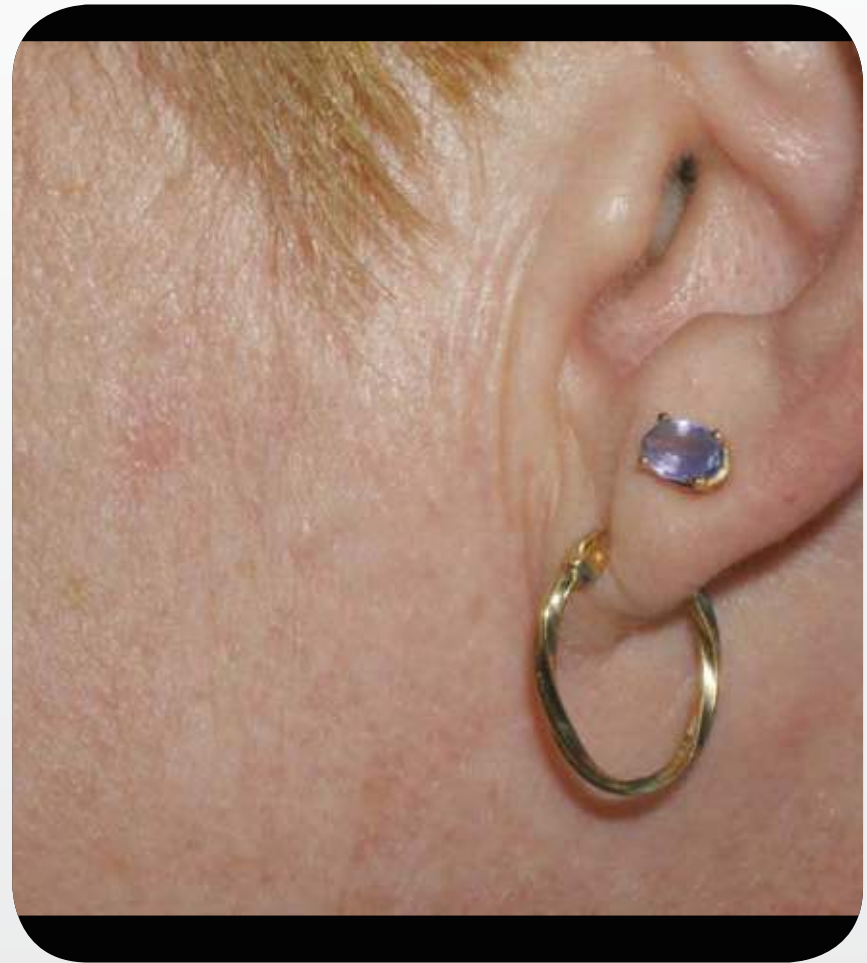Courtesy of David Kaufman, MD

PB-1003880 Rev C

Keratoses



Baseline

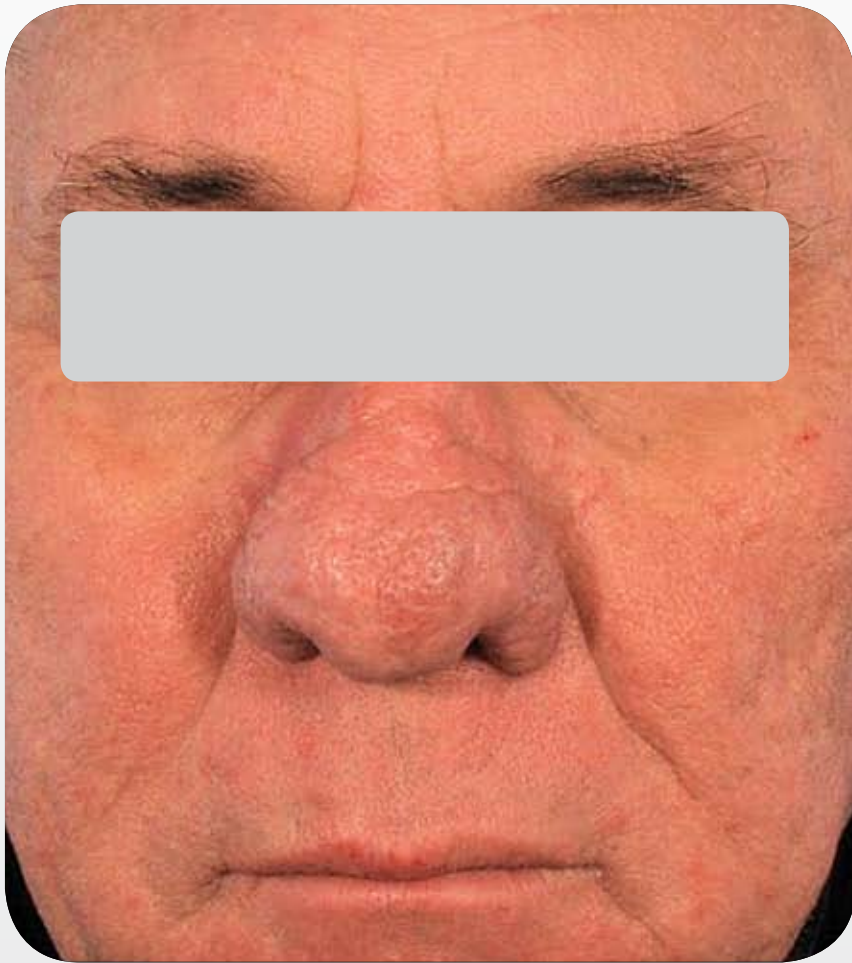


After treatment

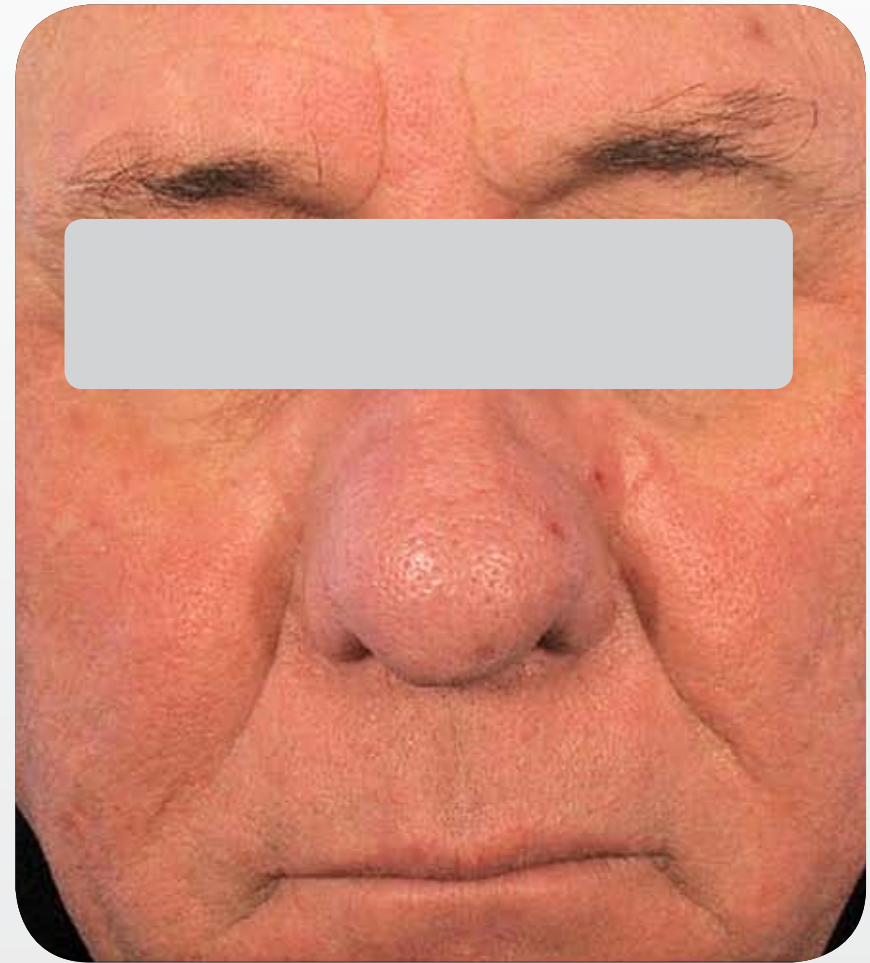
Courtesy of Joseph Niamtu III, DMD

PB-1003880 Rev C

Rhinophyma

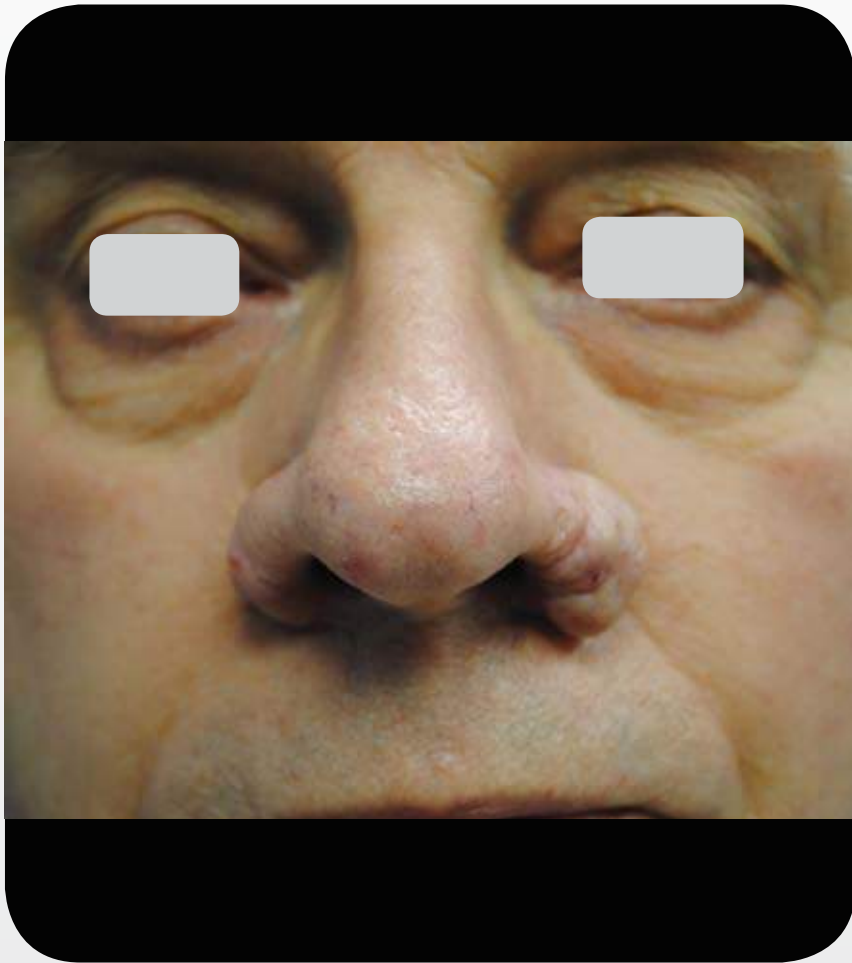


Baseline

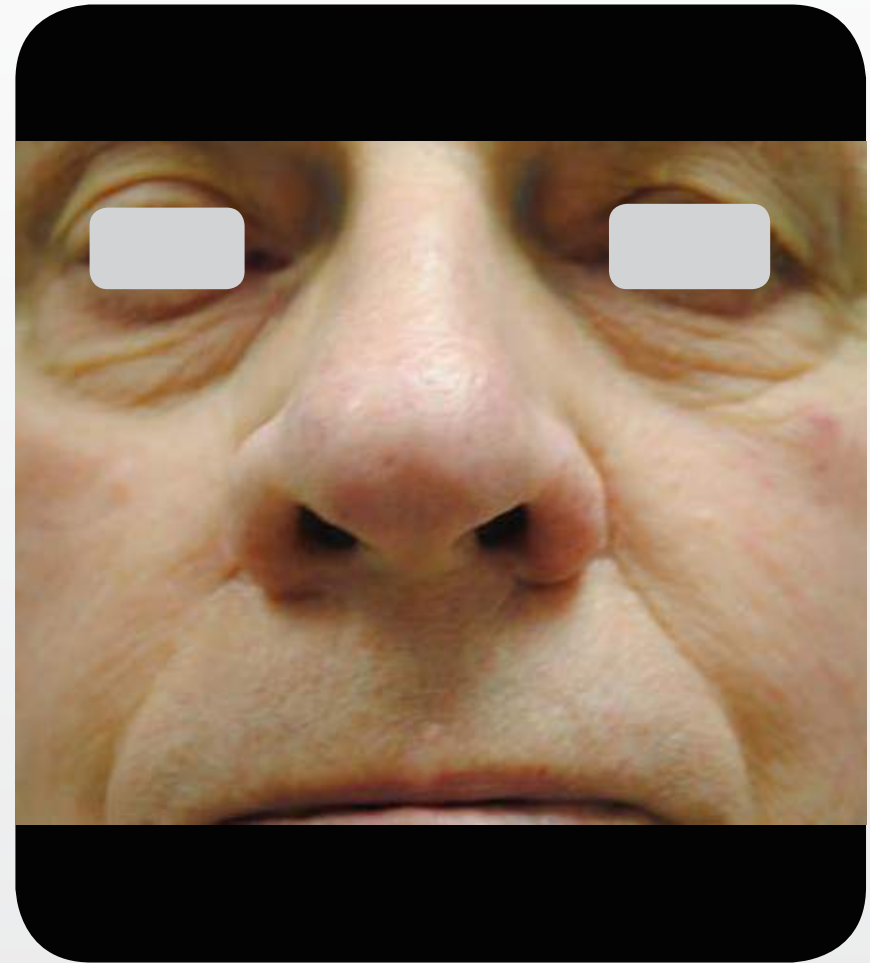


5 months after 1 treatment

Rhinophyma

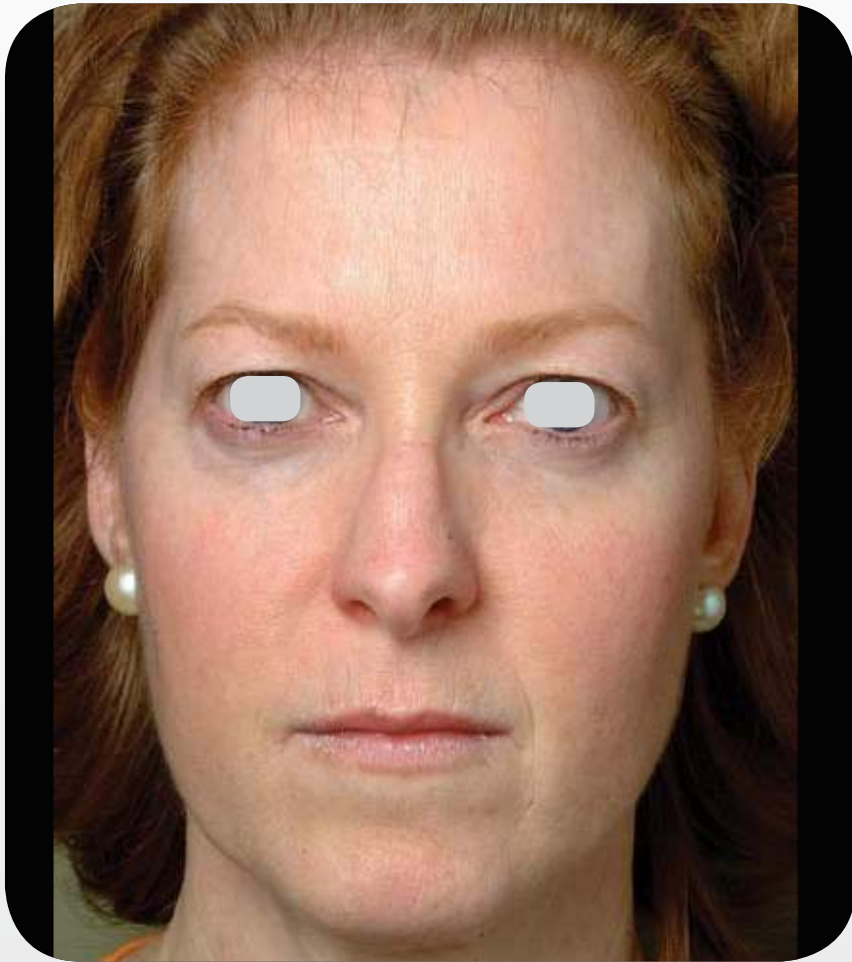

Baseline

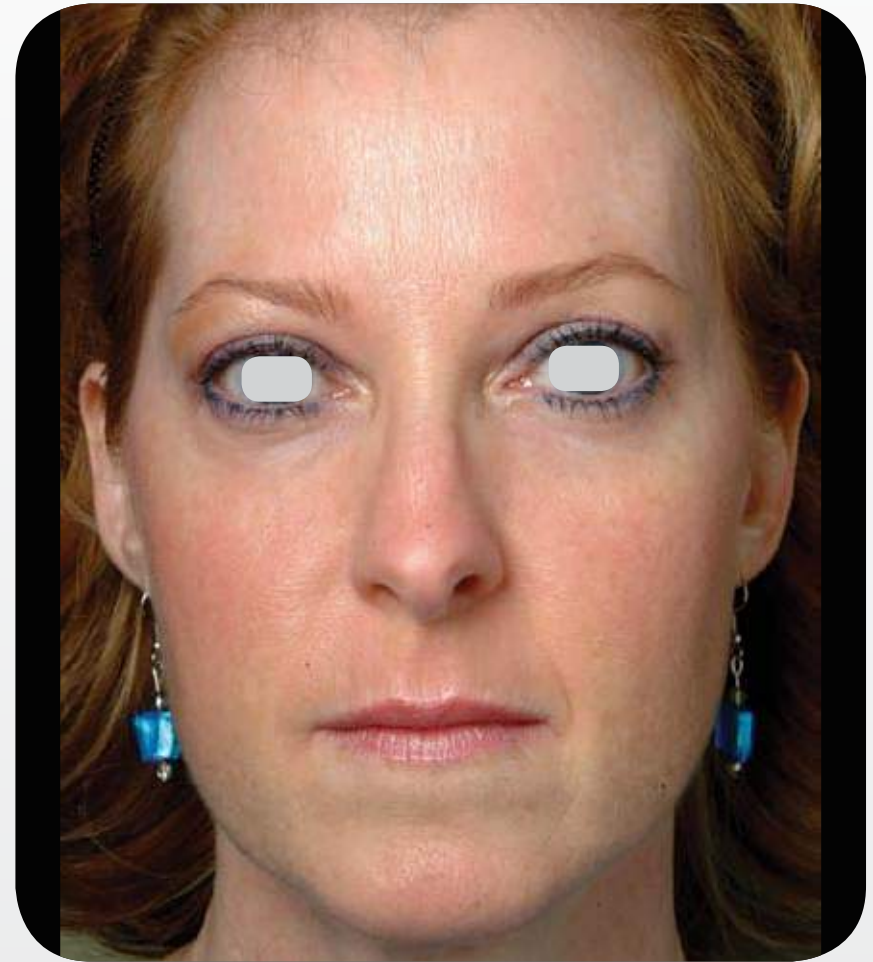

10 weeks after 1 treatment

Blepharoplasty



Baseline

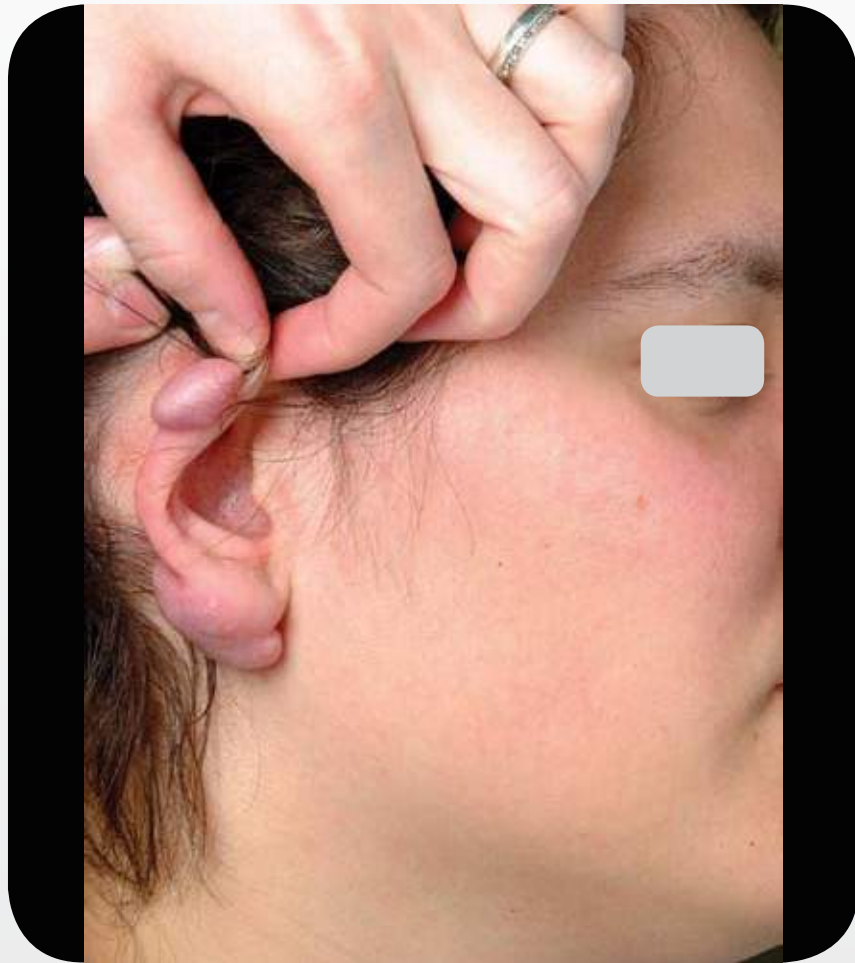


After treatment

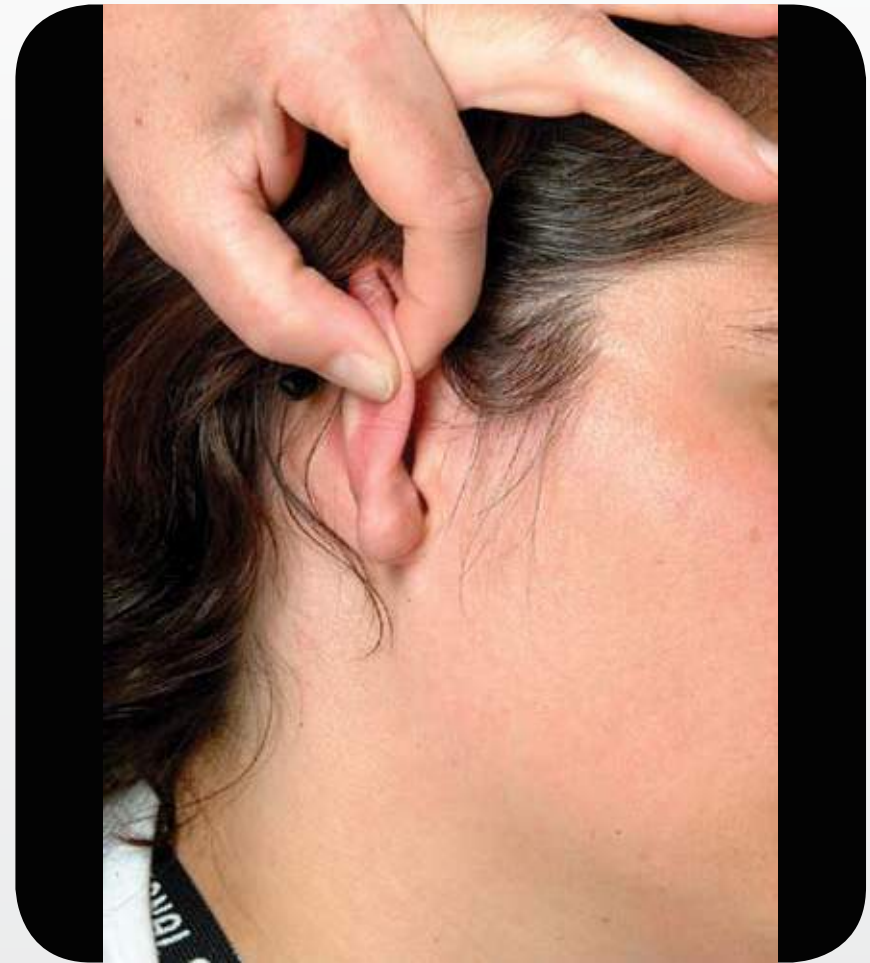
Courtesy of Kent Remington, MD

PB-1003880 Rev C

Scar Revision



Baseline

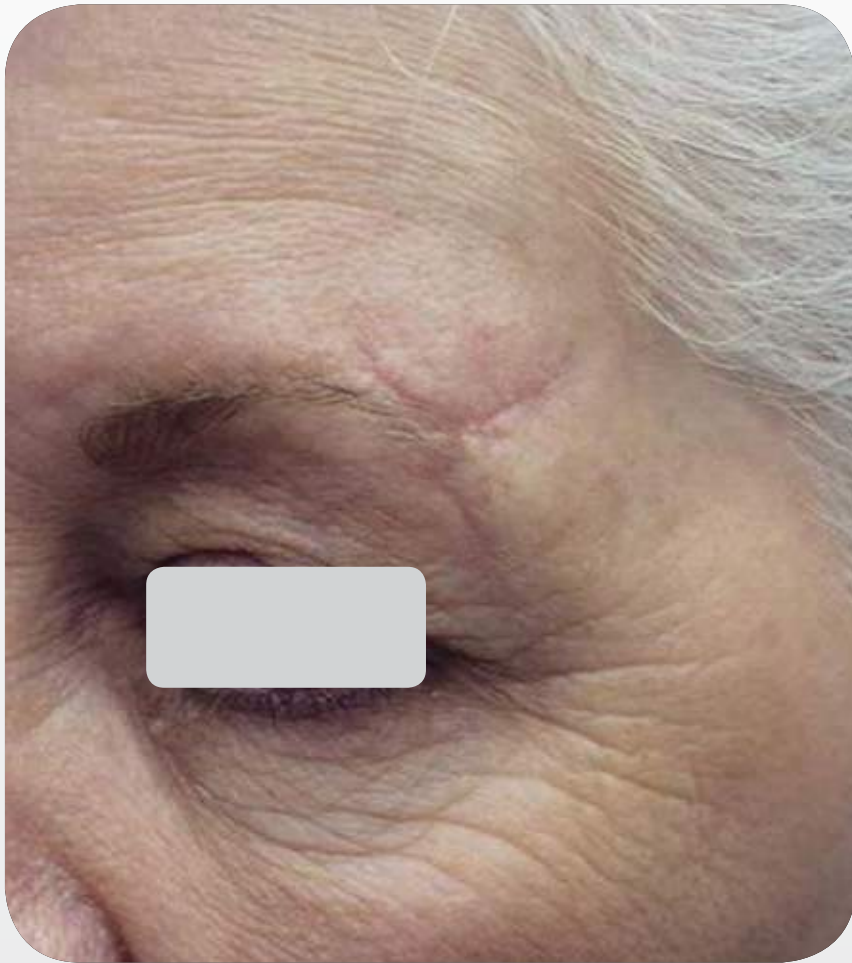

After treatment

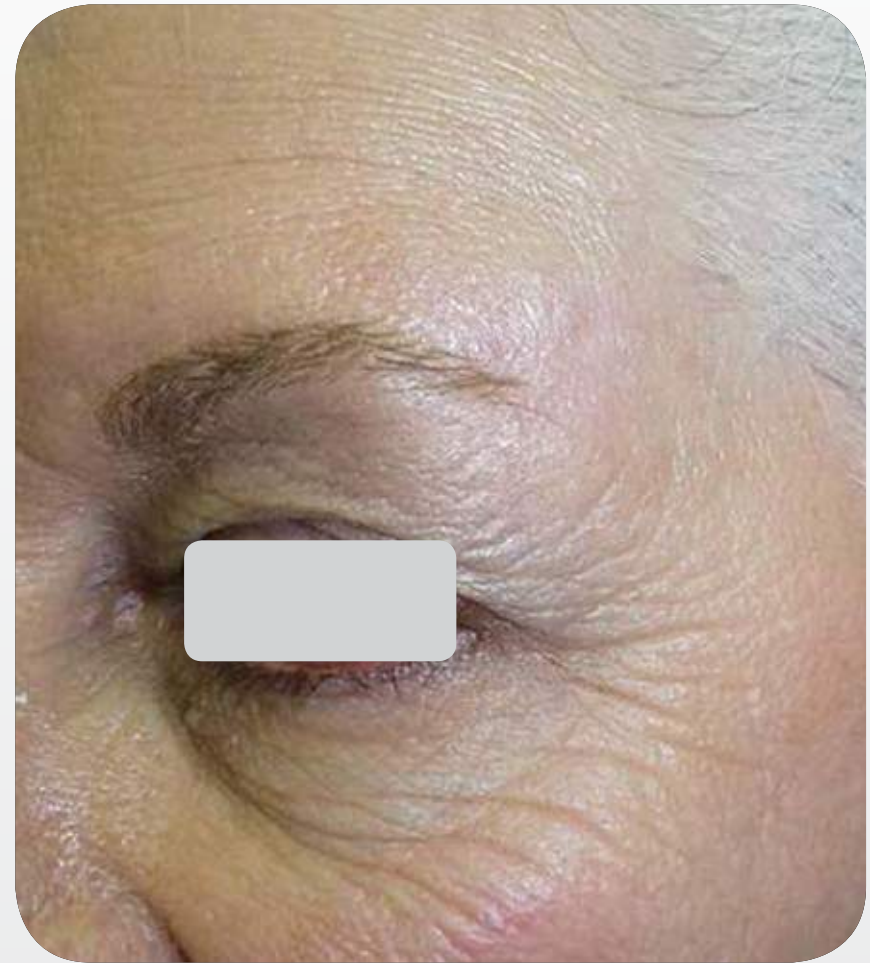Courtesy of Kent Remington, MD

PB-1003880 Rev C

Scar Revision



Baseline

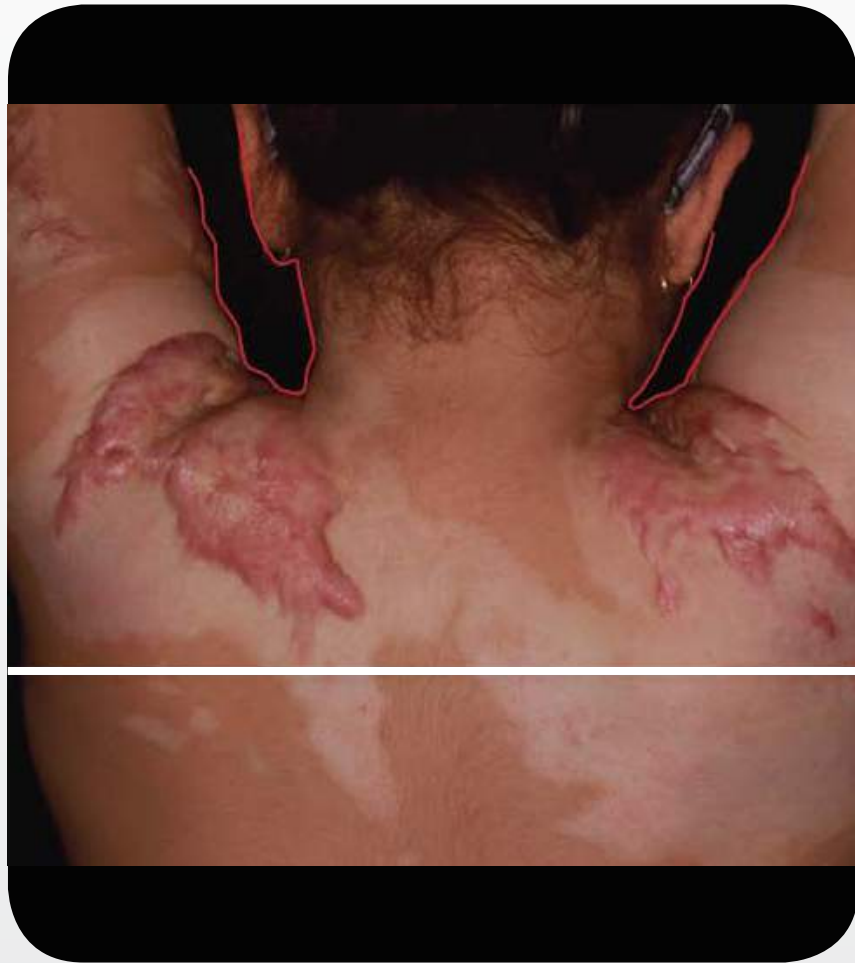

After treatment

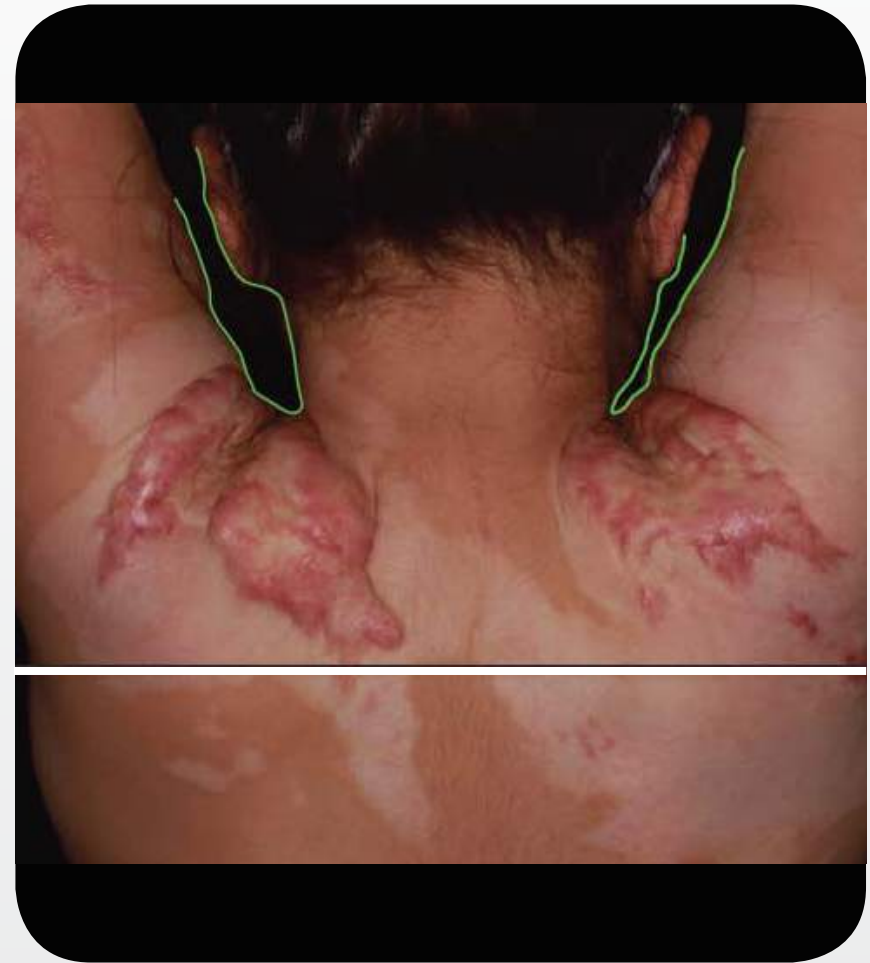Courtesy of Joseph Niamtu III, DMD

PB-1003880 Rev C

Scar Revision



Baseline

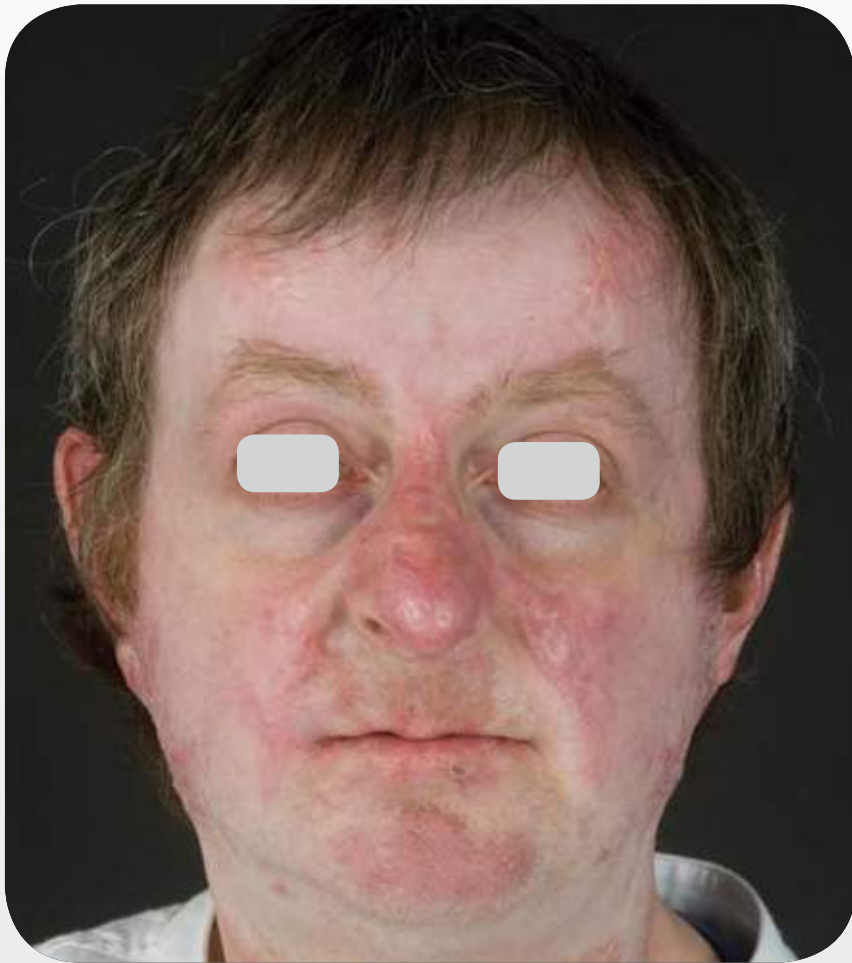

After 1 treatment

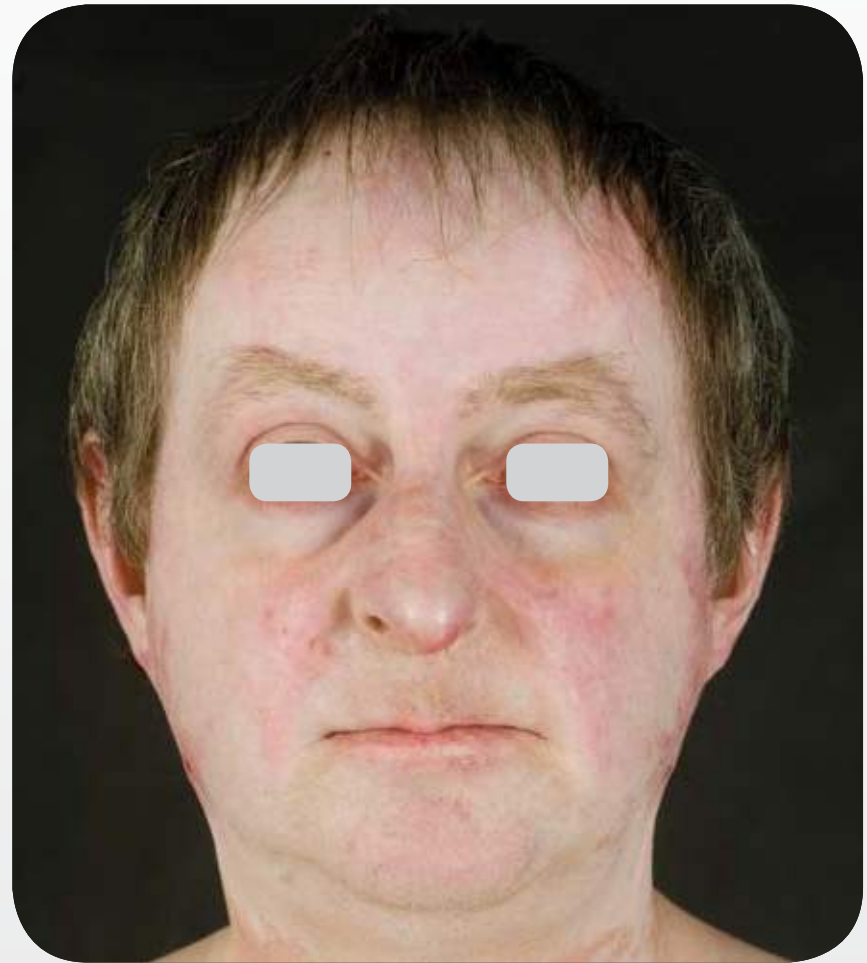
Courtesy of Matteo Tretti Clementoni, MD

PB-1003880 Rev C

Scar Revision



Baseline

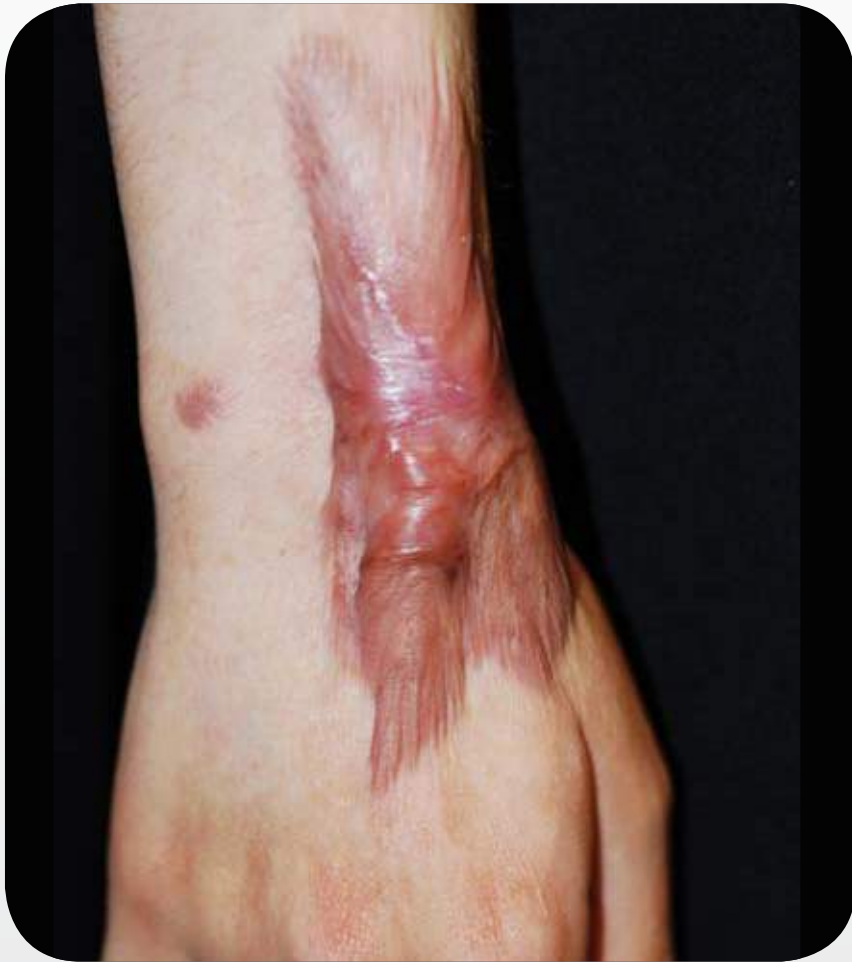

After treatment

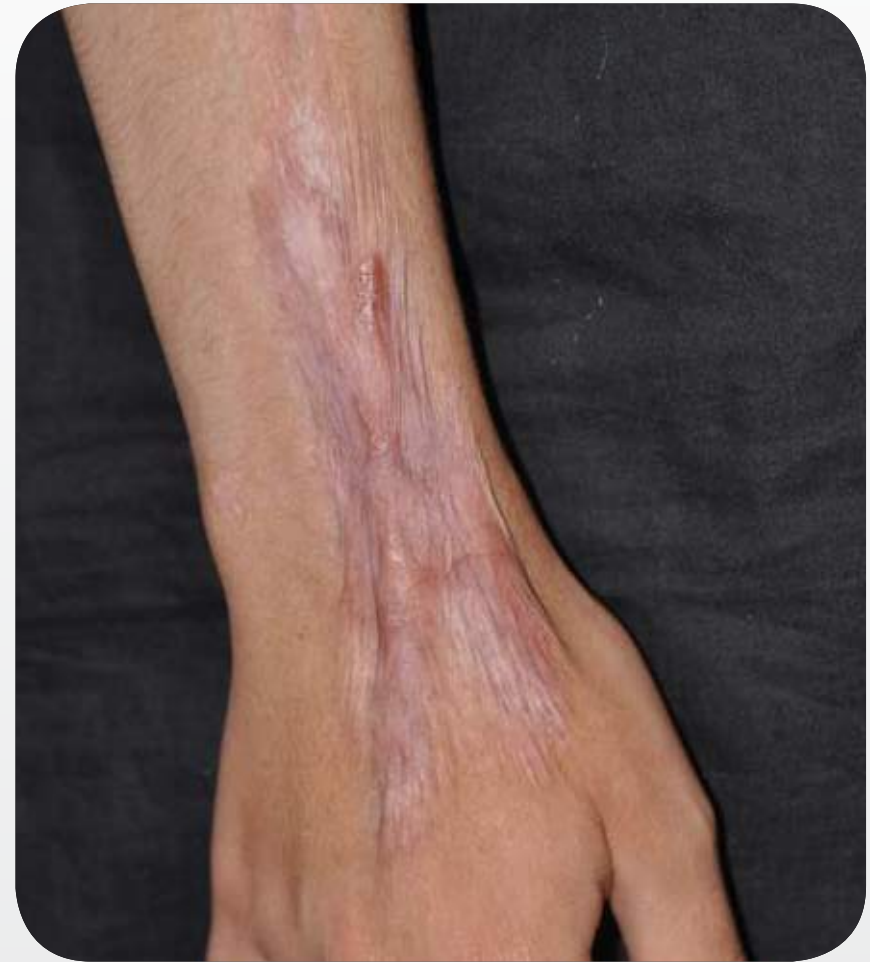Courtesy of Max Murison, MD

PB-1003880 Rev C

Scar Revision

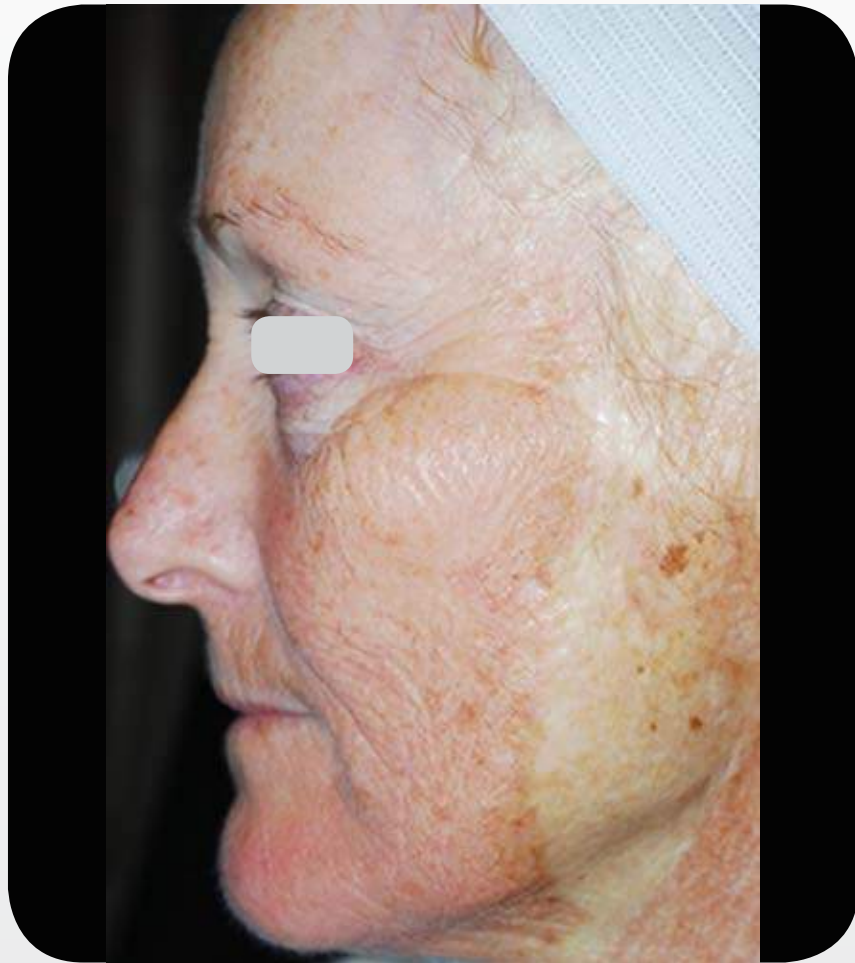

Baseline

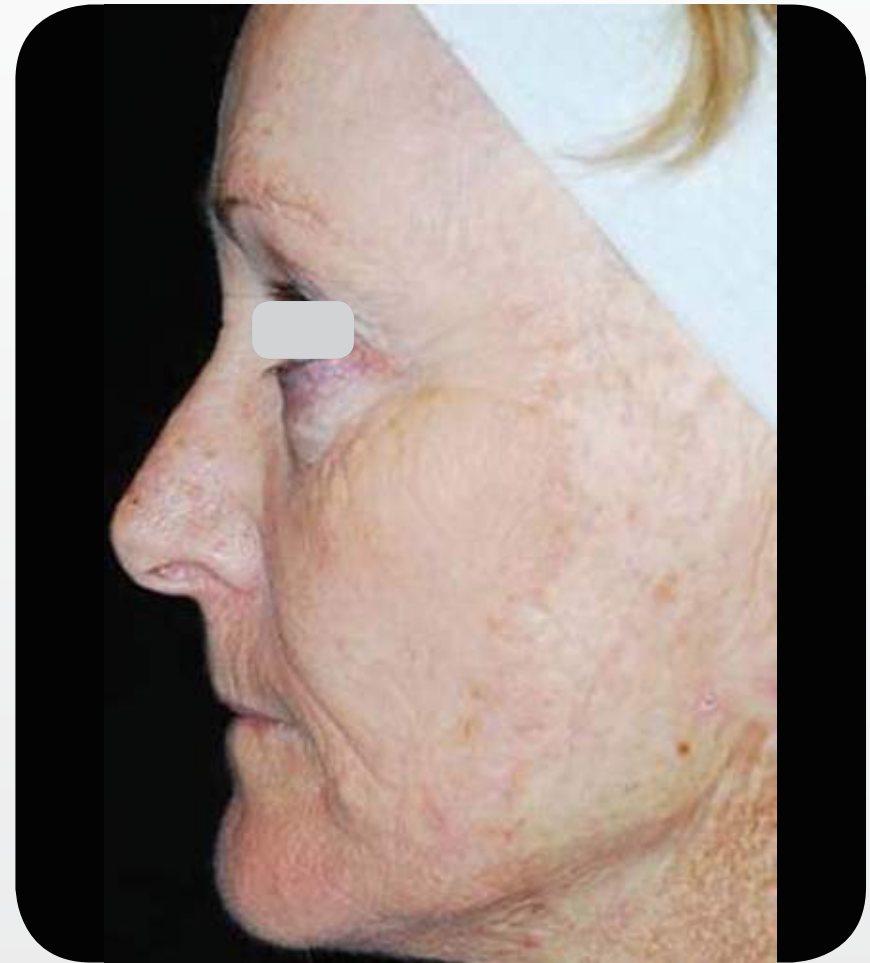

2 years after treatment

Scar Revision



Baseline

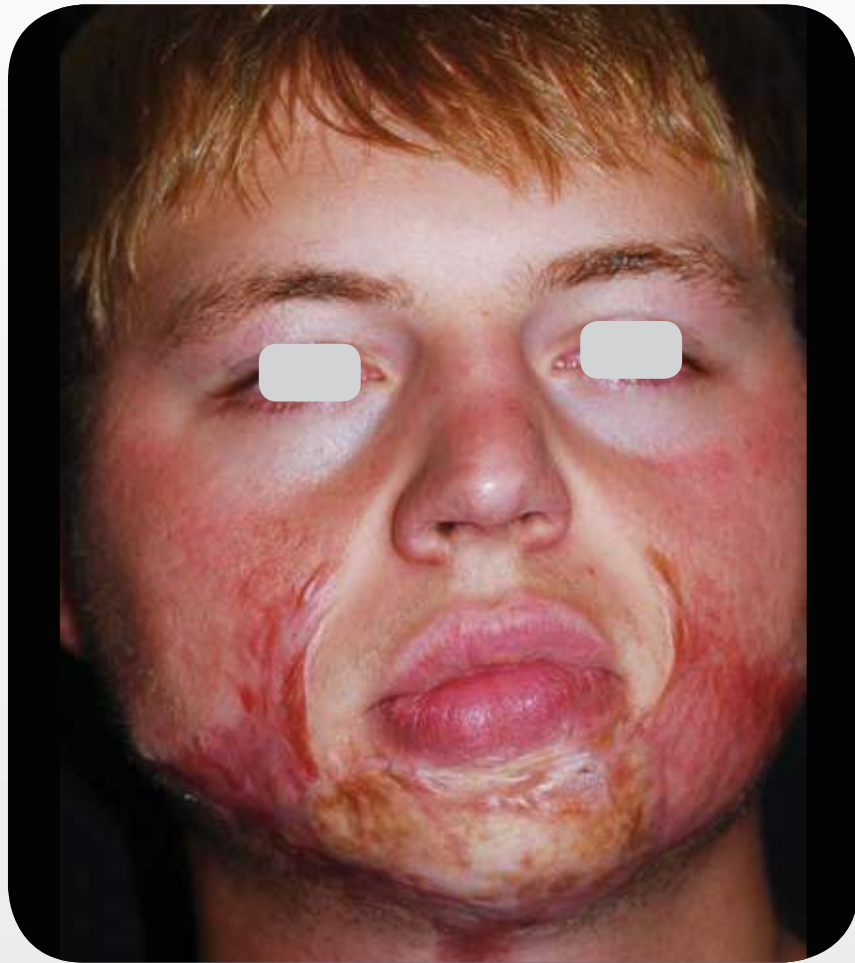


After treatment

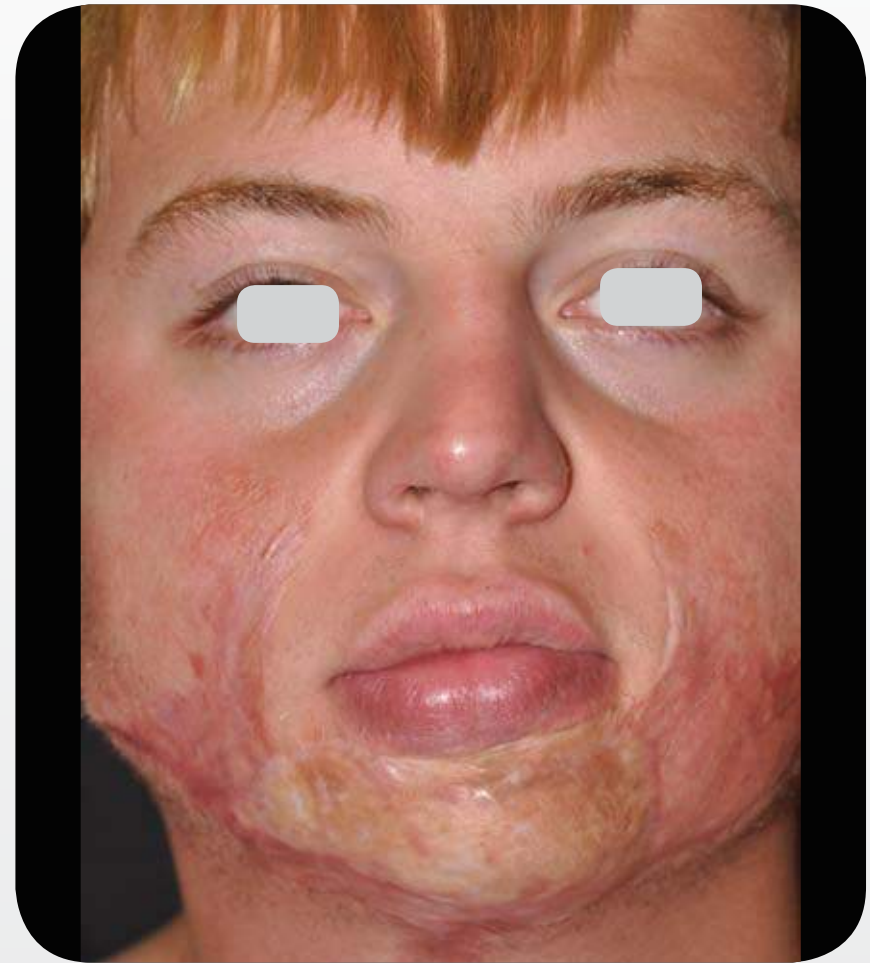
Courtesy of Jill S. Waibel, MD

PB-1003880 Rev C

Scar Revision



Baseline

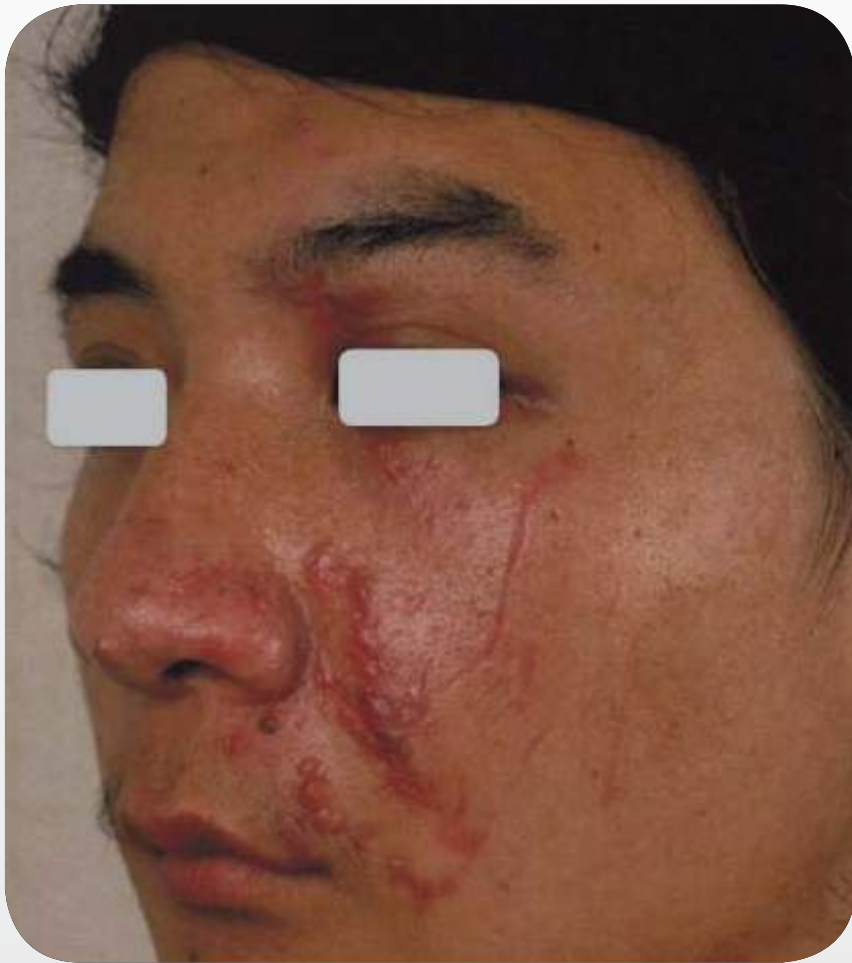

After treatment

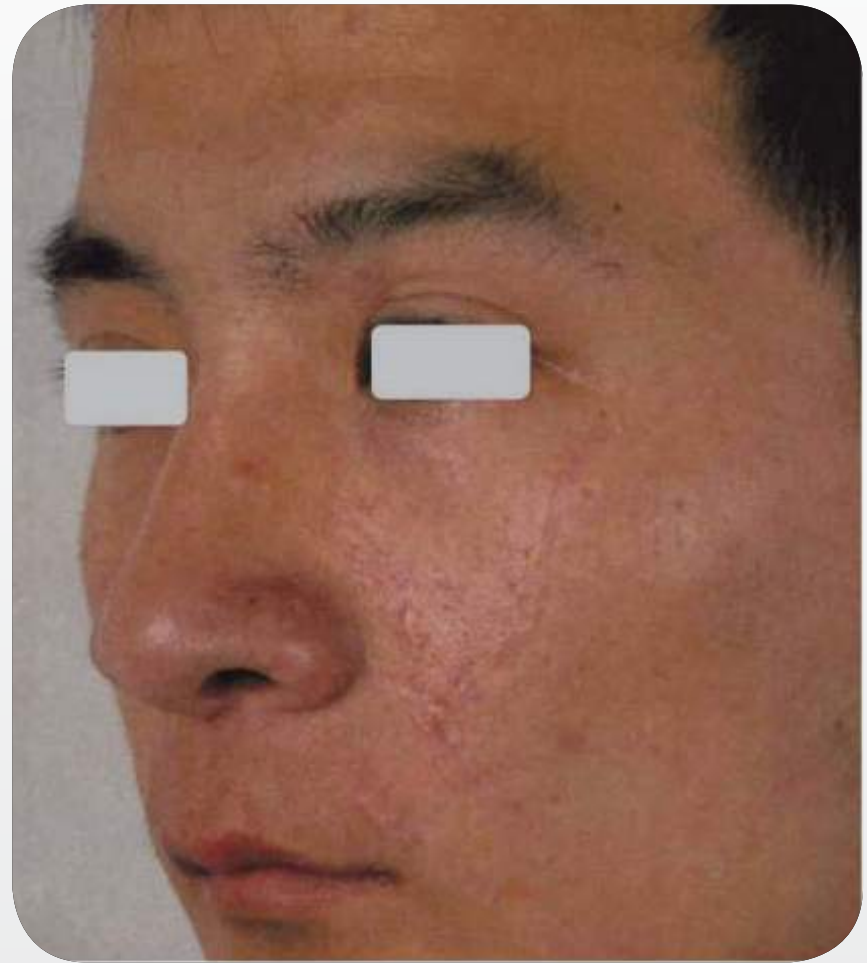
Courtesy of Jill S. Waibel, MD

PB-1003880 Rev C

Scar Revision combined with PDL



Baseline

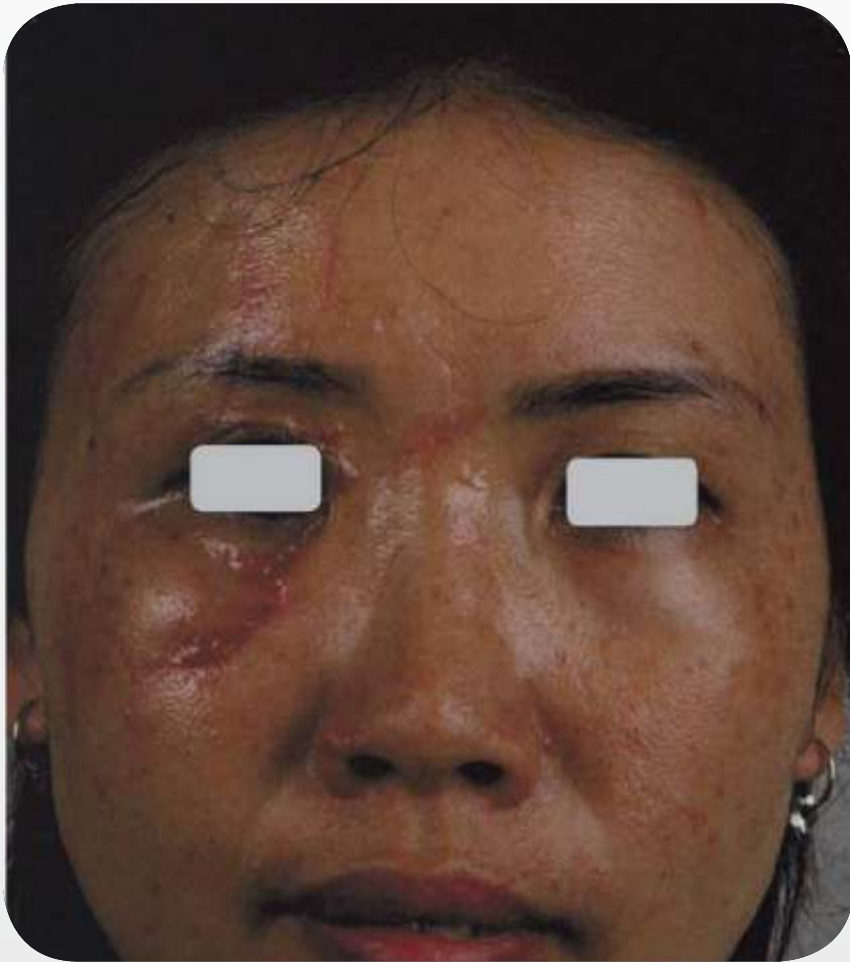

After treatment

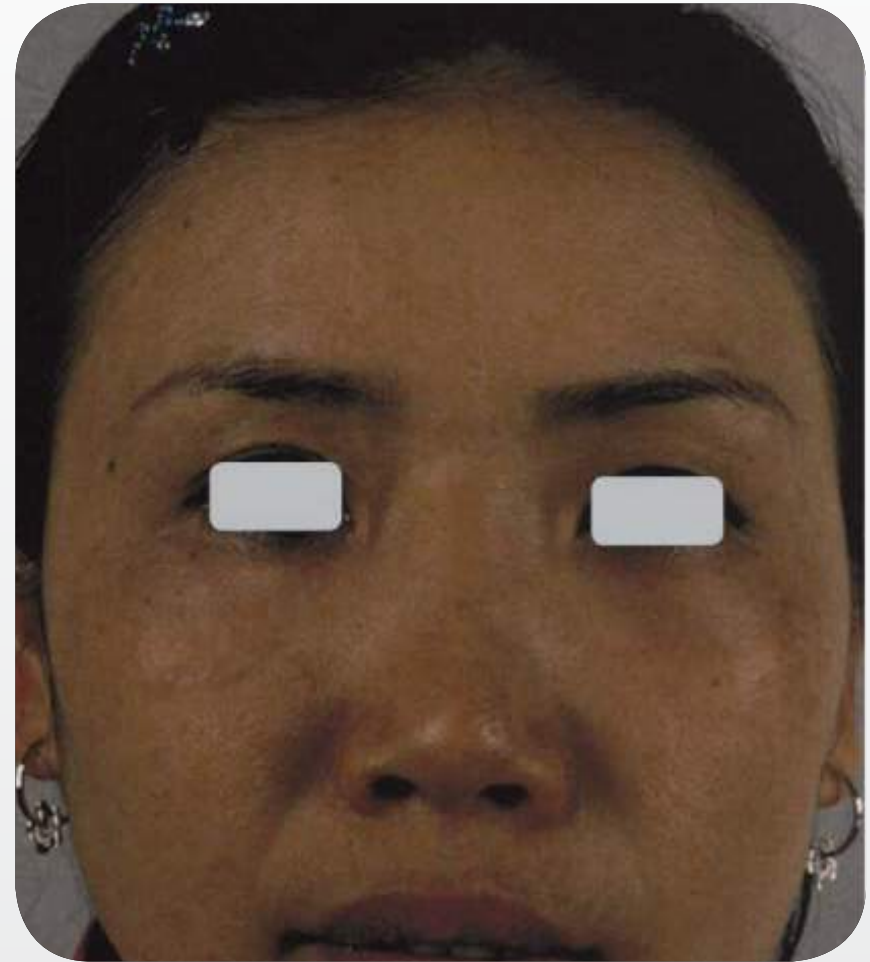Courtesy of Tan Jun, MD

PB-1003880 Rev C

Scar Revision combined with PDL



Baseline

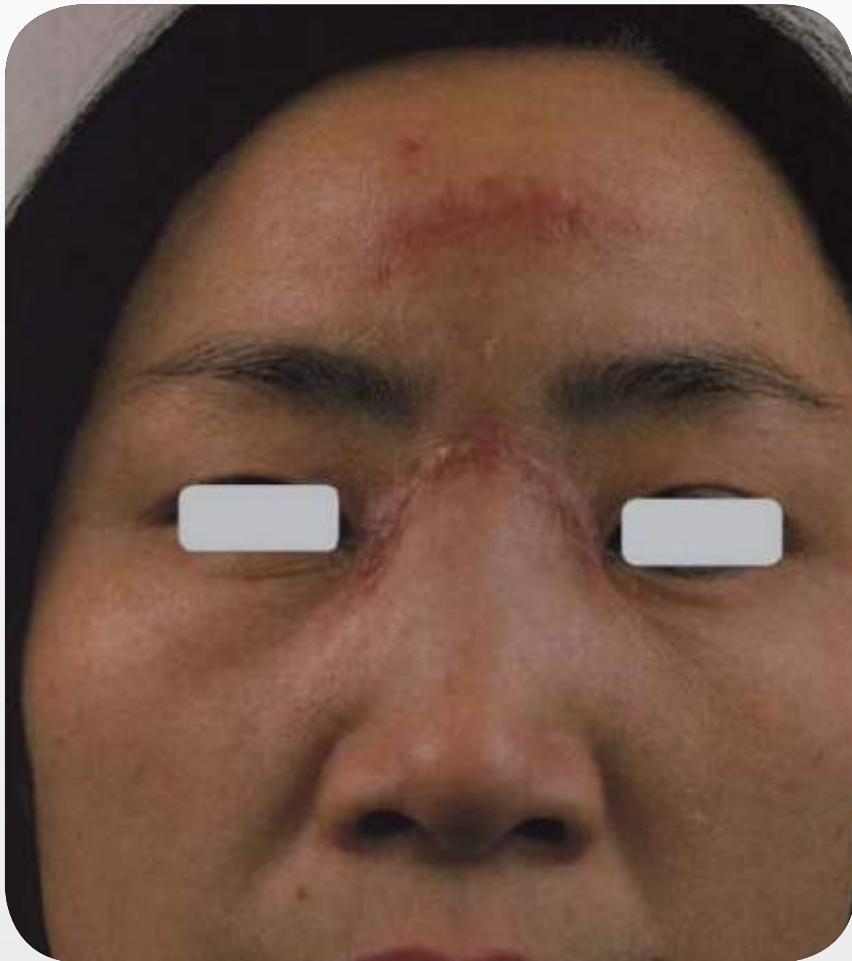

After treatment

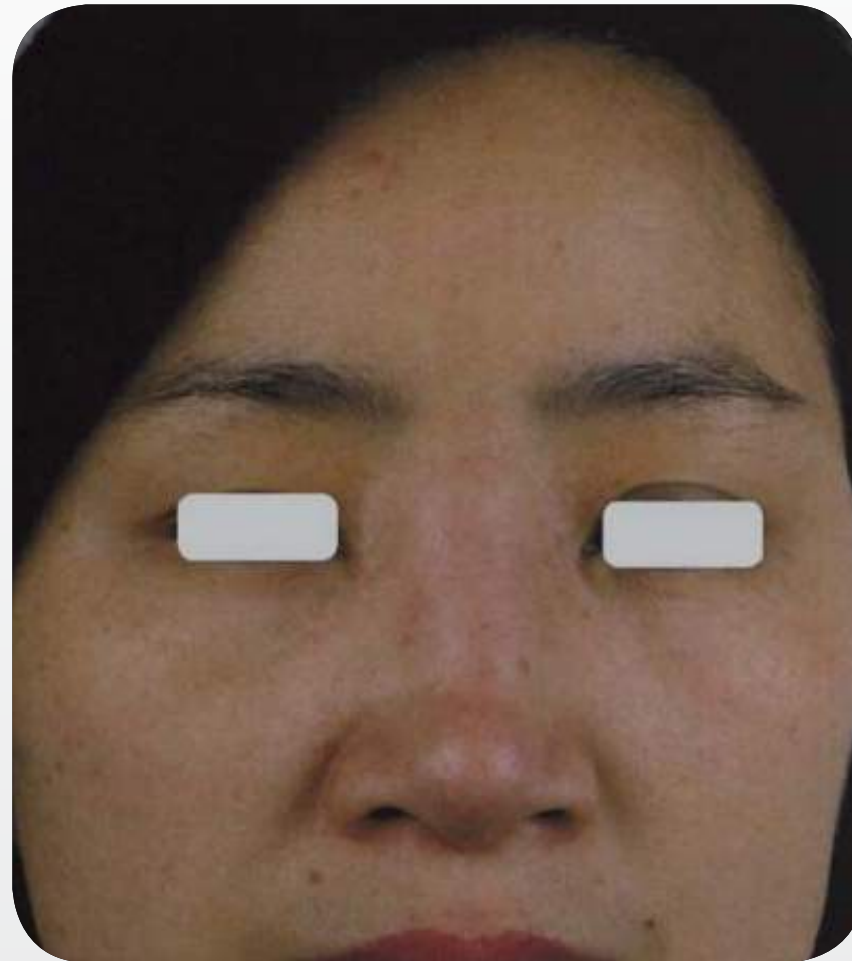
Courtesy of Tan Jun, MD

PB-1003880 Rev C

Scar Revision combined with PDL



Baseline

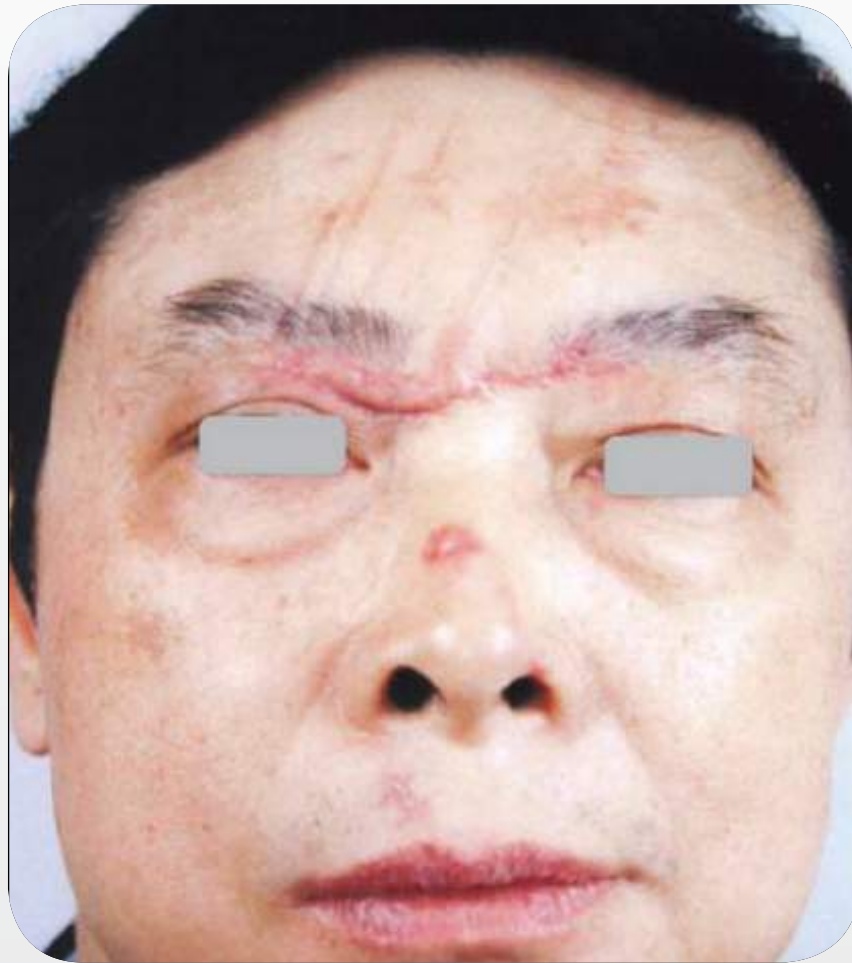

After treatment

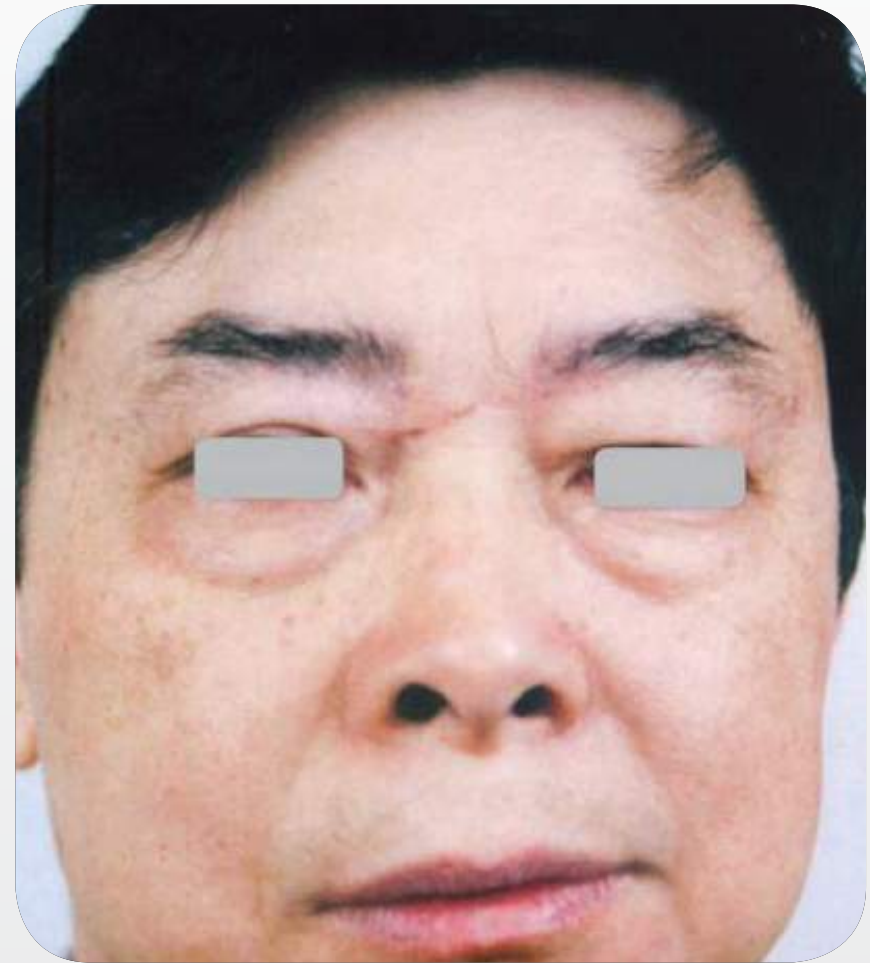Courtesy of Tan Jun, MD

PB-1003880 Rev C

Scar Revision combined with VPW532



Baseline

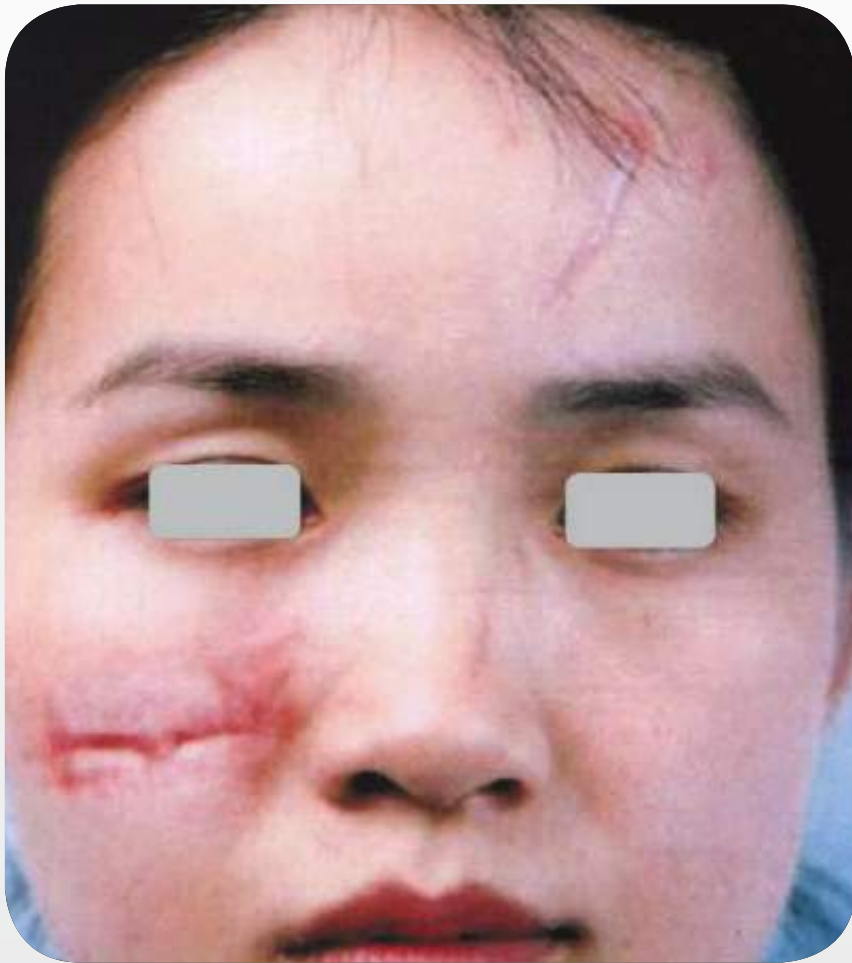

After treatment

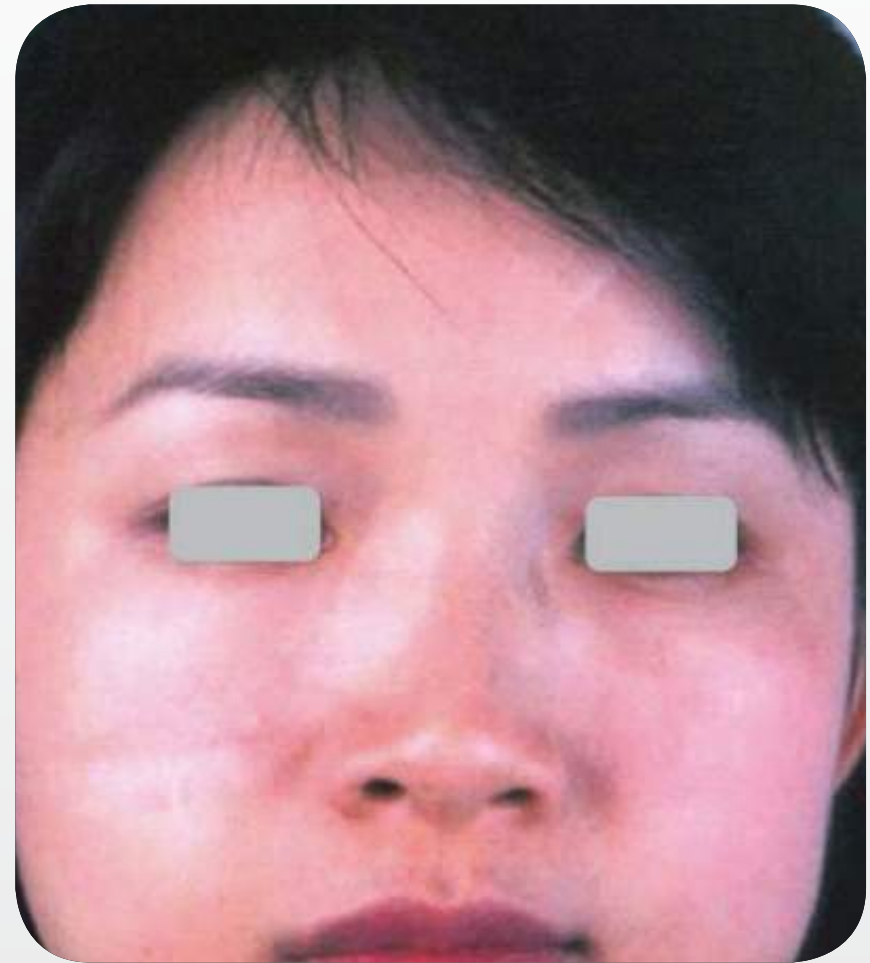
Courtesy of Tan Jun, MD

PB-1003880 Rev C

Scar Revision combined with PDL



Baseline

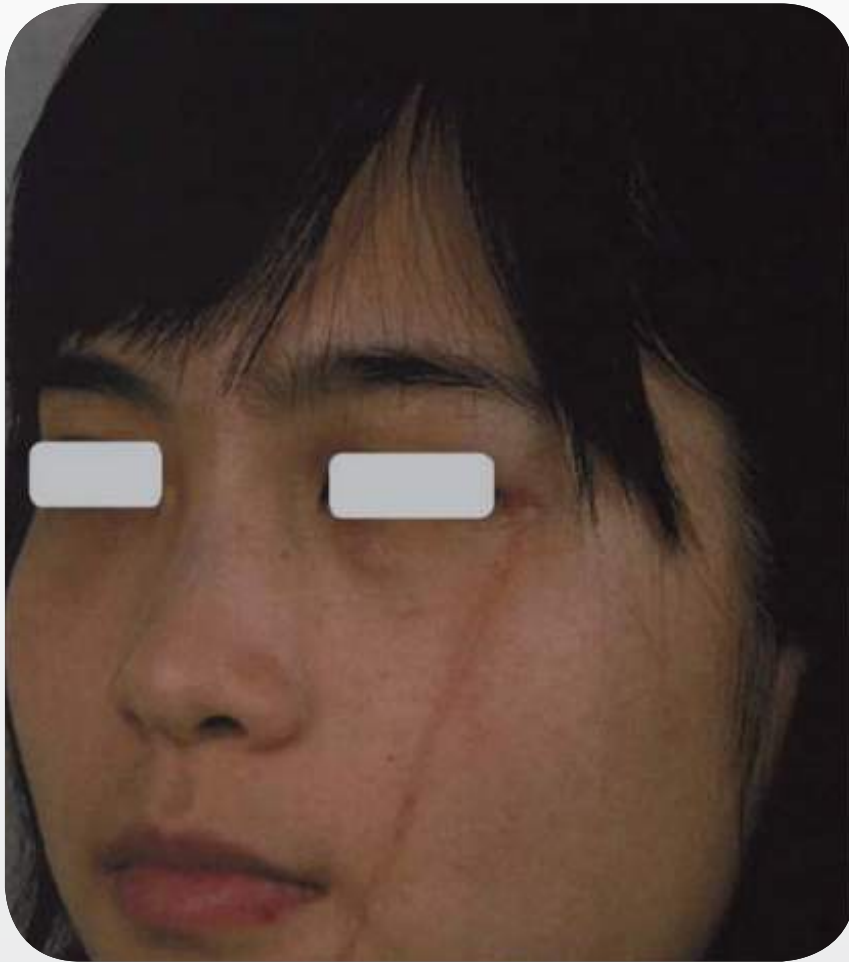


After treatment

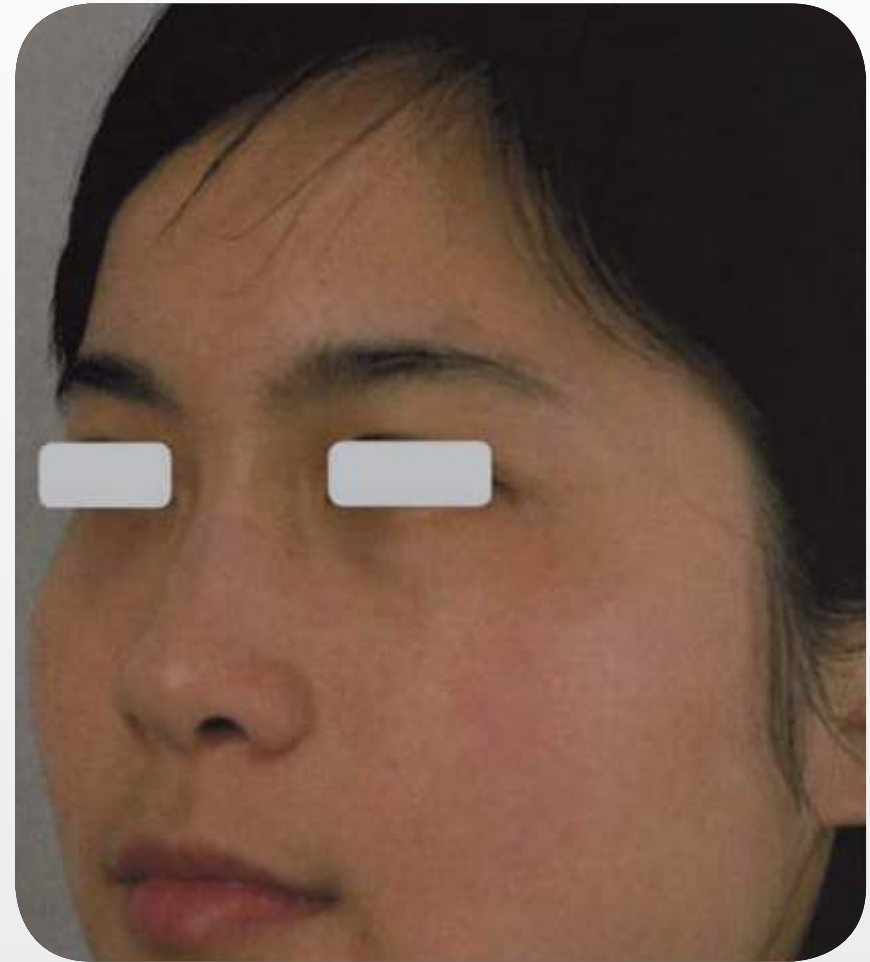
Courtesy of Tan Jun, MD

PB-1003880 Rev C

Scar Revision combined with PDL



Baseline

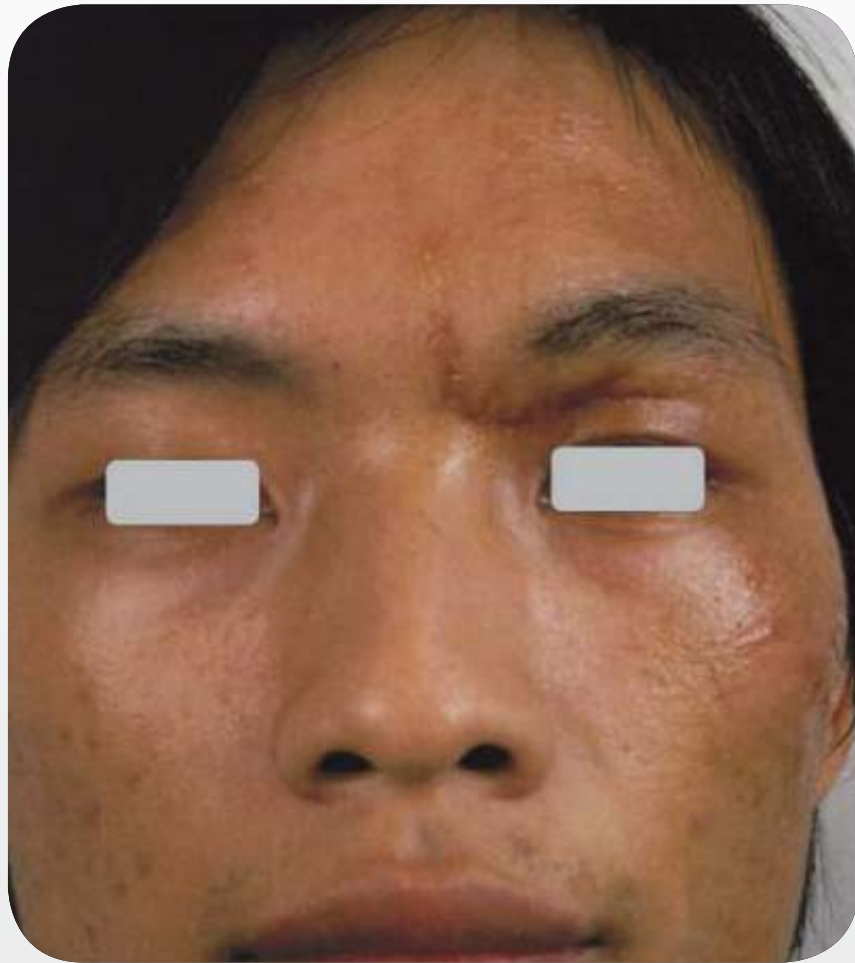

After treatment

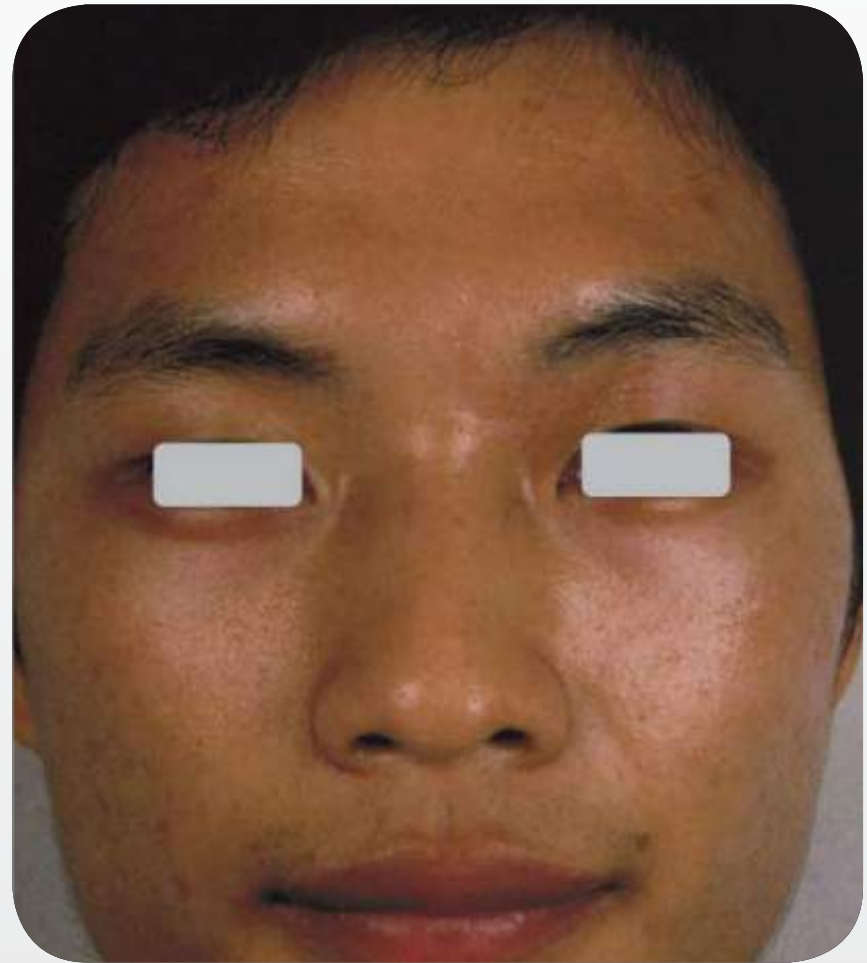
Courtesy of Tan Jun, MD

PB-1003880 Rev C

Scar Revision combined with PDL



Baseline

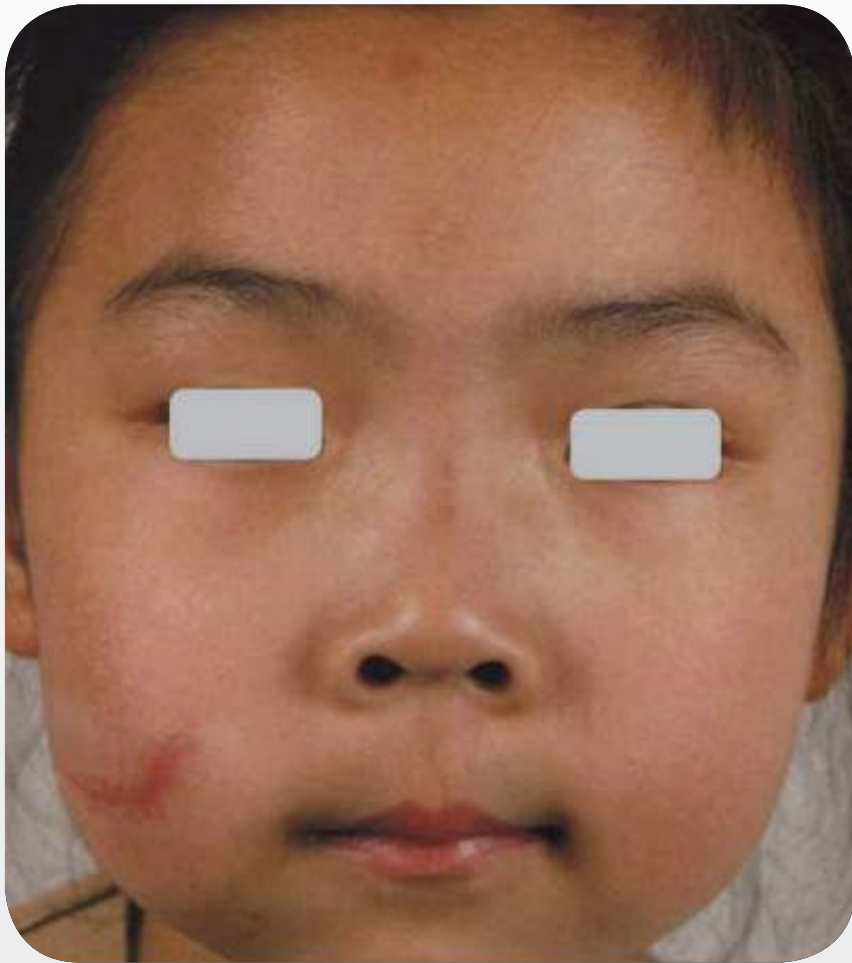

After treatment

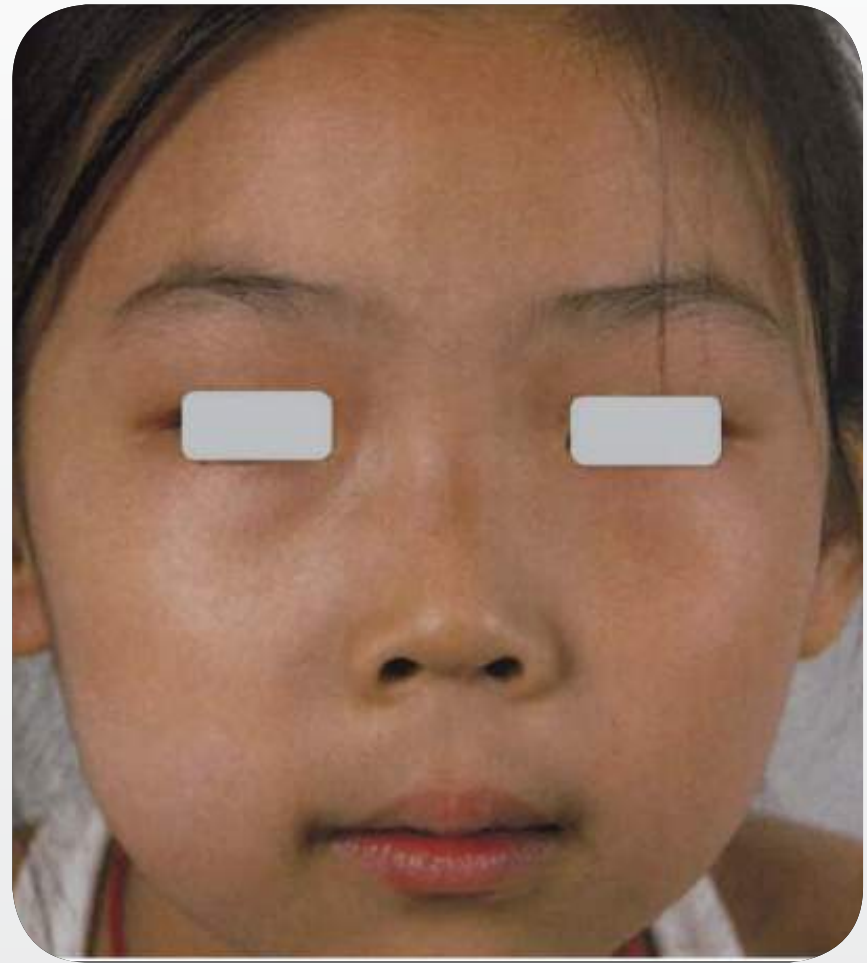
Courtesy of Tan Jun, MD

PB-1003880 Rev C

Scar Revision combined with PDL



Baseline

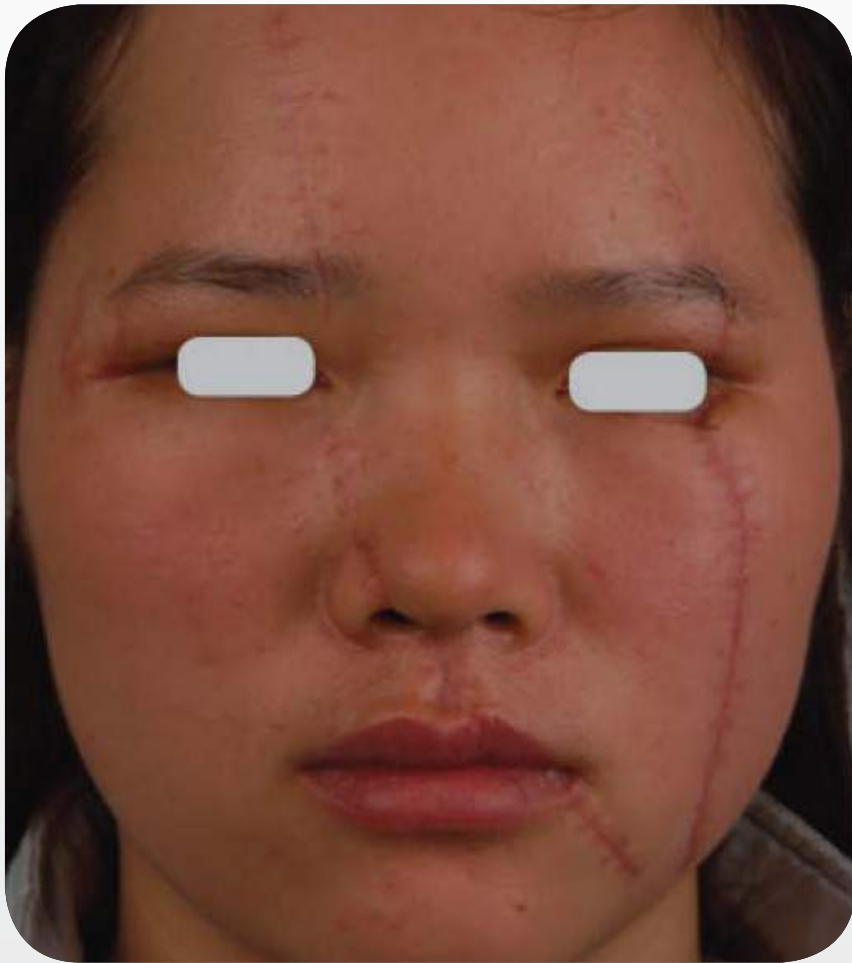


After treatment

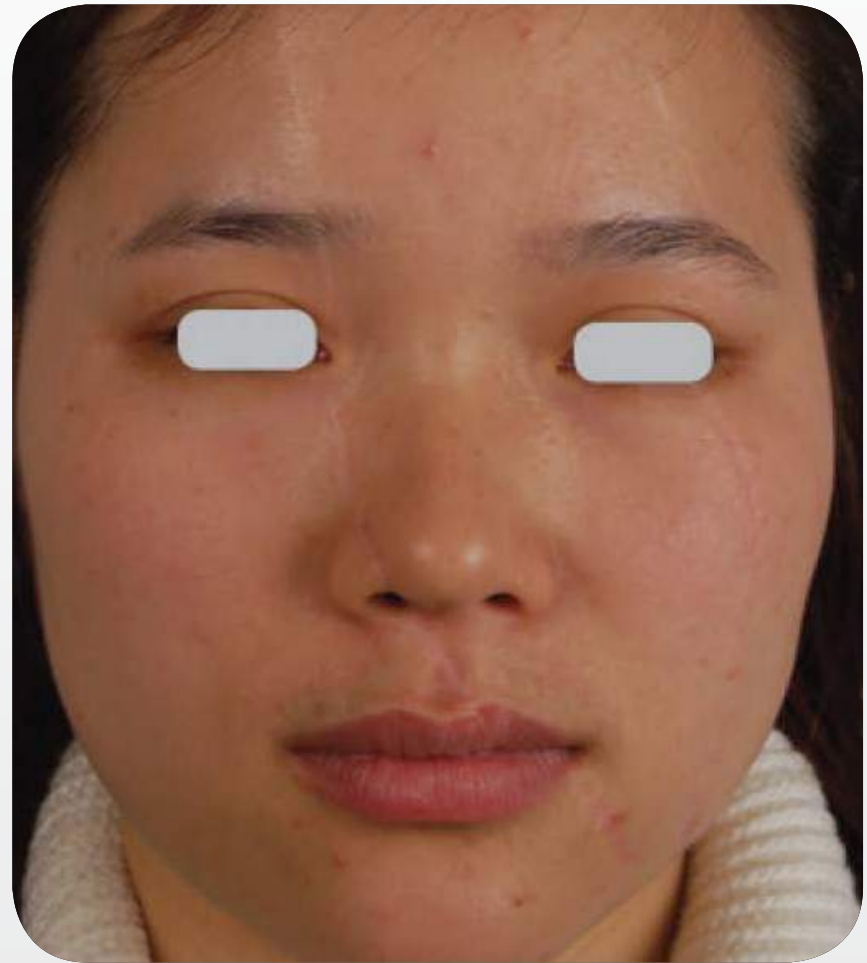
Courtesy of Tan Jun, MD

PB-1003880 Rev C

Scar Revision combined with VPW532



Baseline

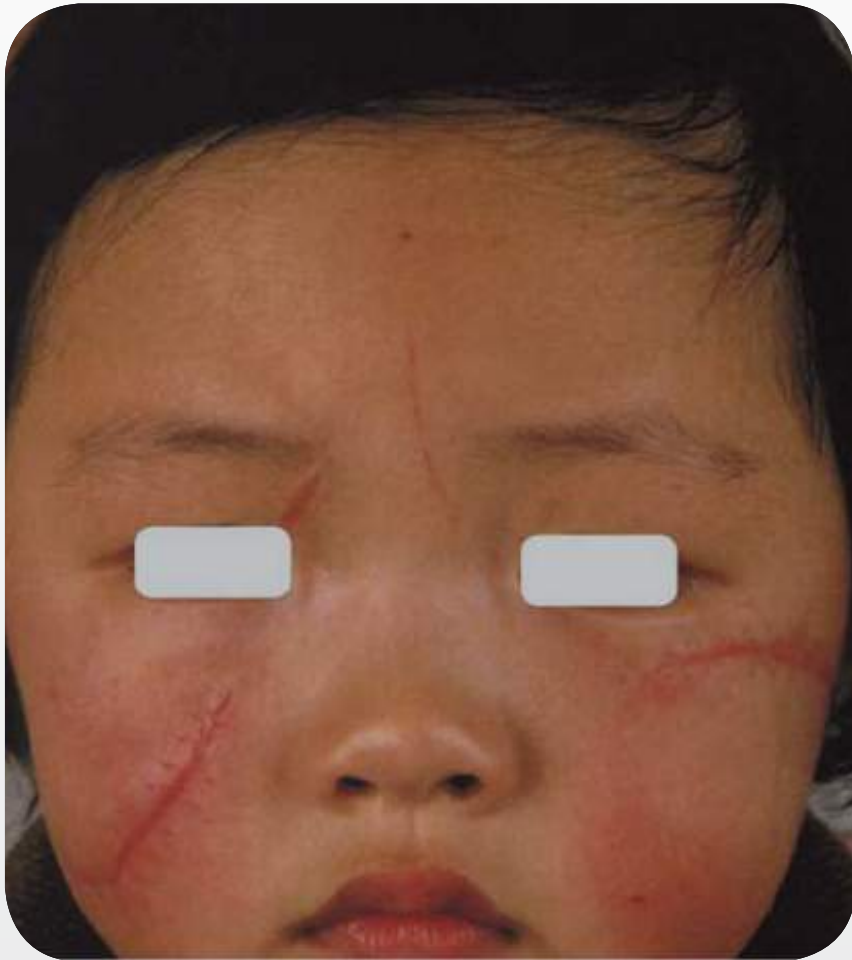

After treatment

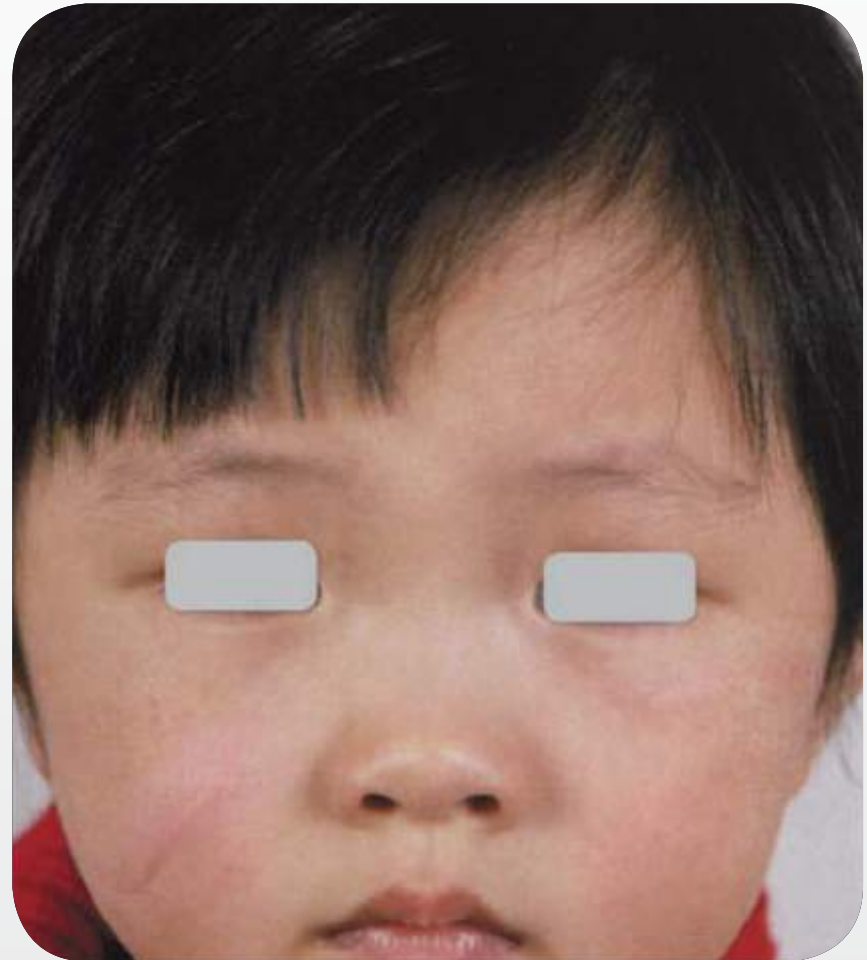
Courtesy of Tan Jun, MD

PB-1003880 Rev C

Scar Revision combined with PDL



Baseline

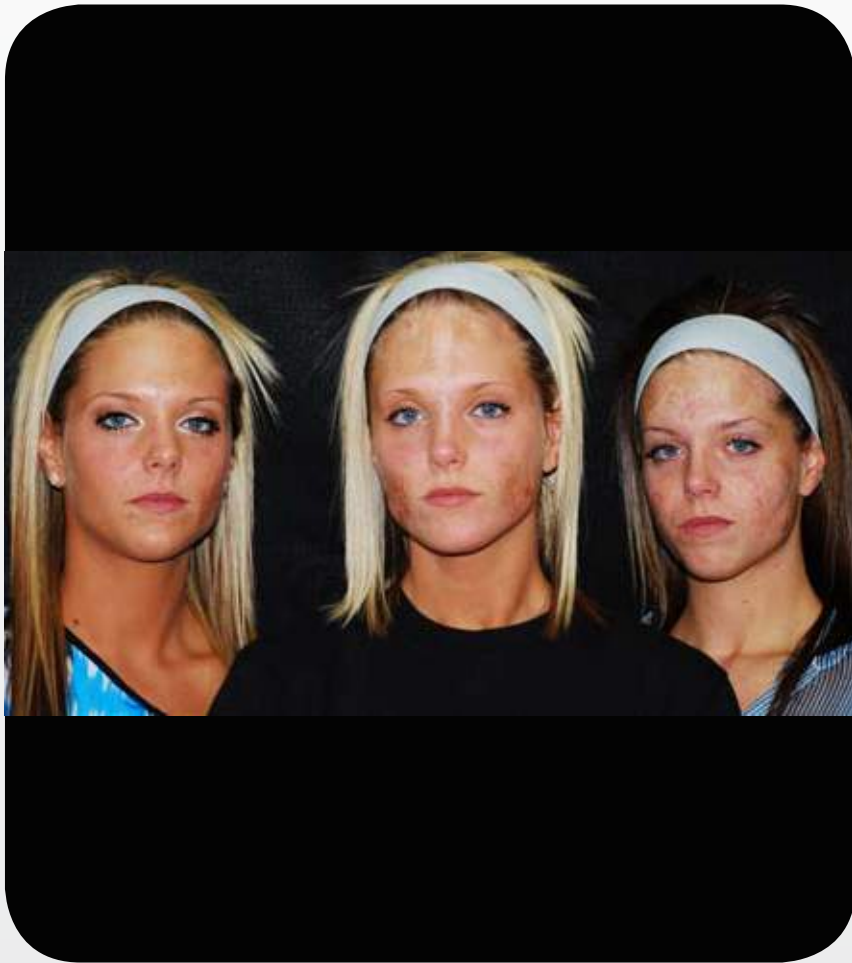

After treatment


Courtesy of Tan Jun, MD

PB-1003880 Rev C

Scar Revision The Berns Triplets; Chandra, Trae & Jordan

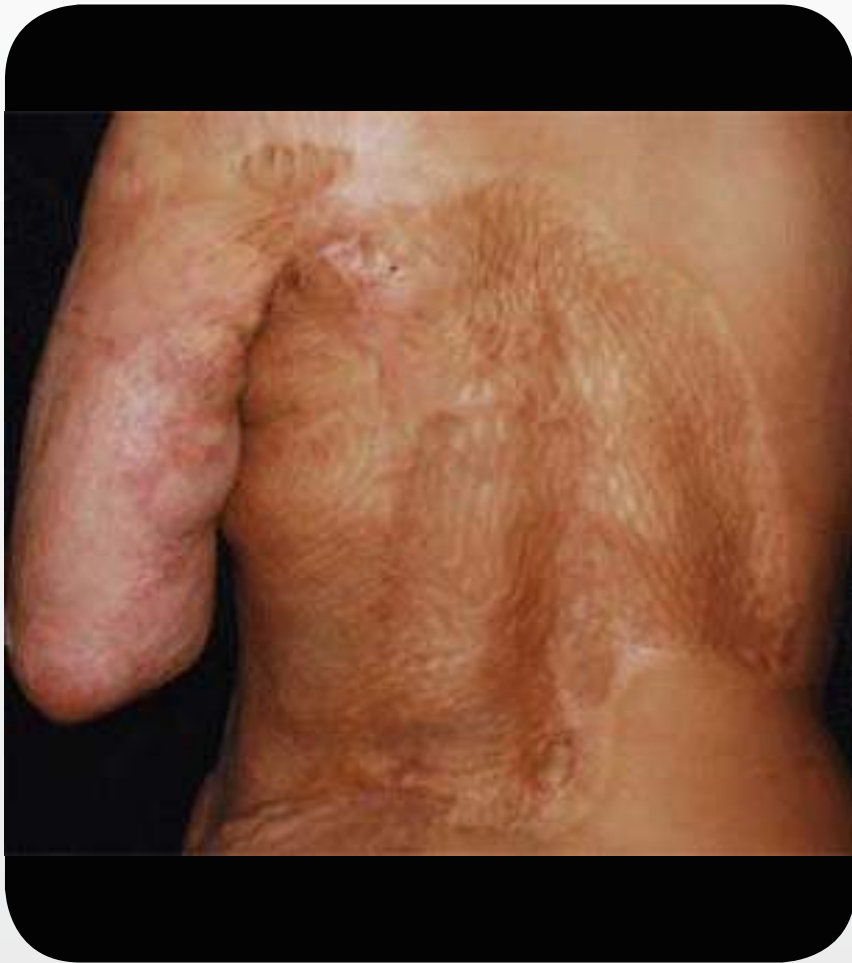

Baseline

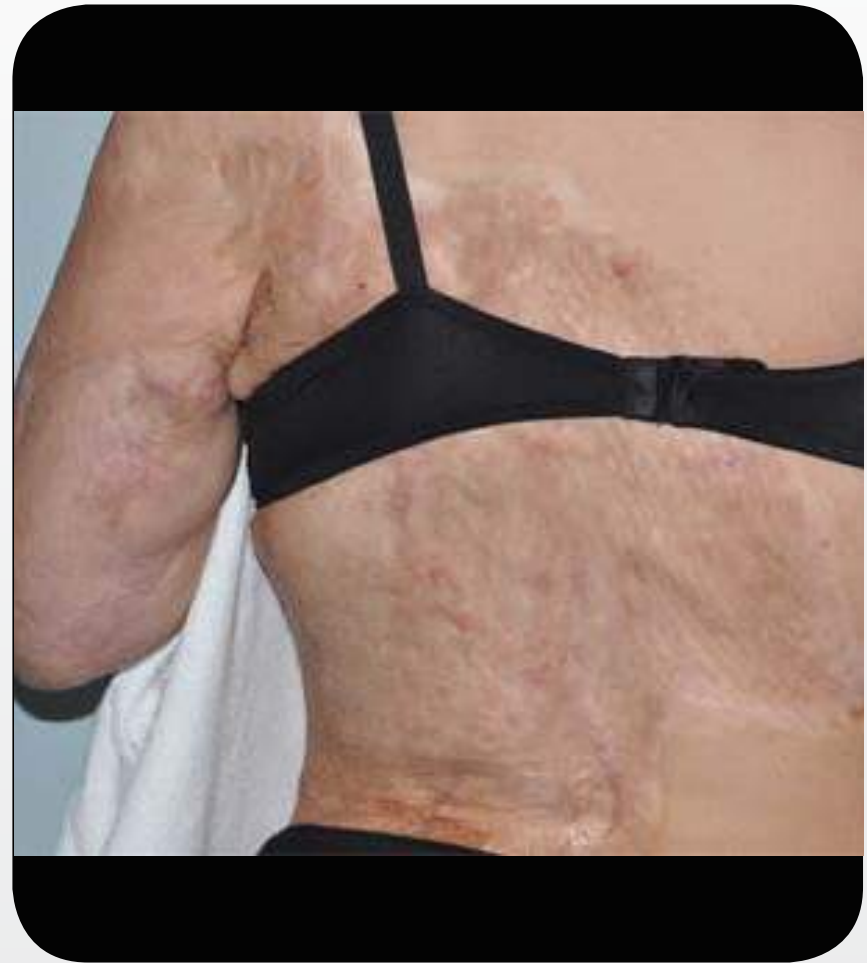

After treatment

Scar Revision The Berns Triplets; Chandra, Trae & Jordan

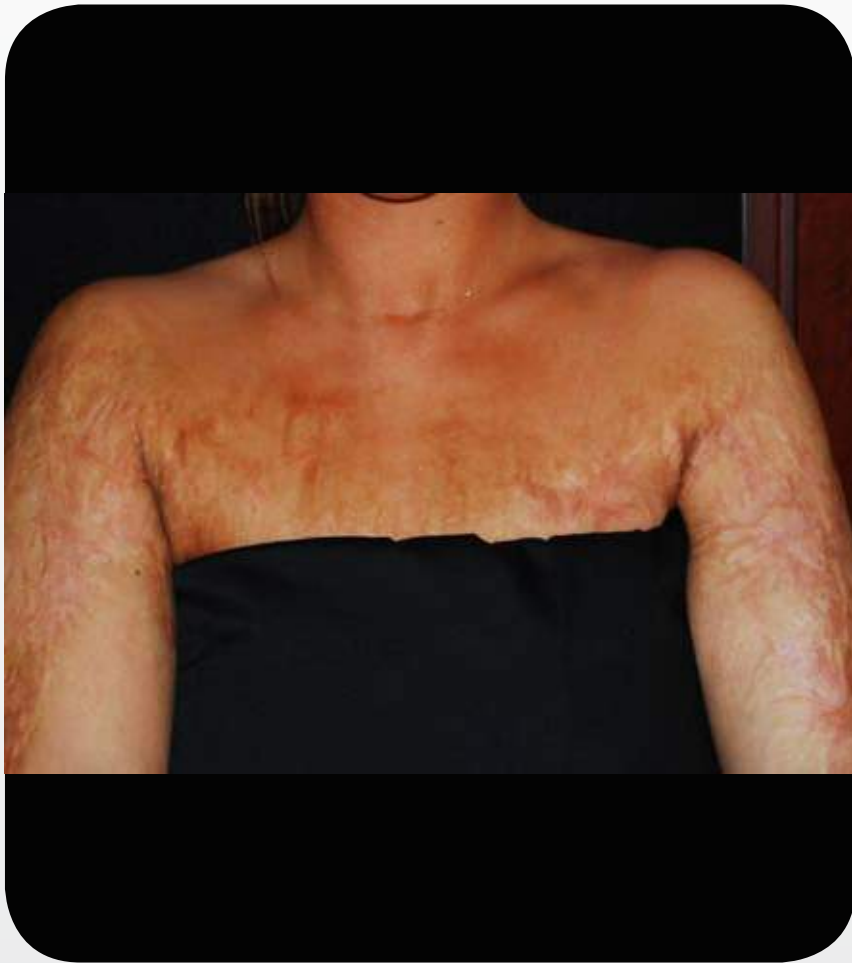

Baseline

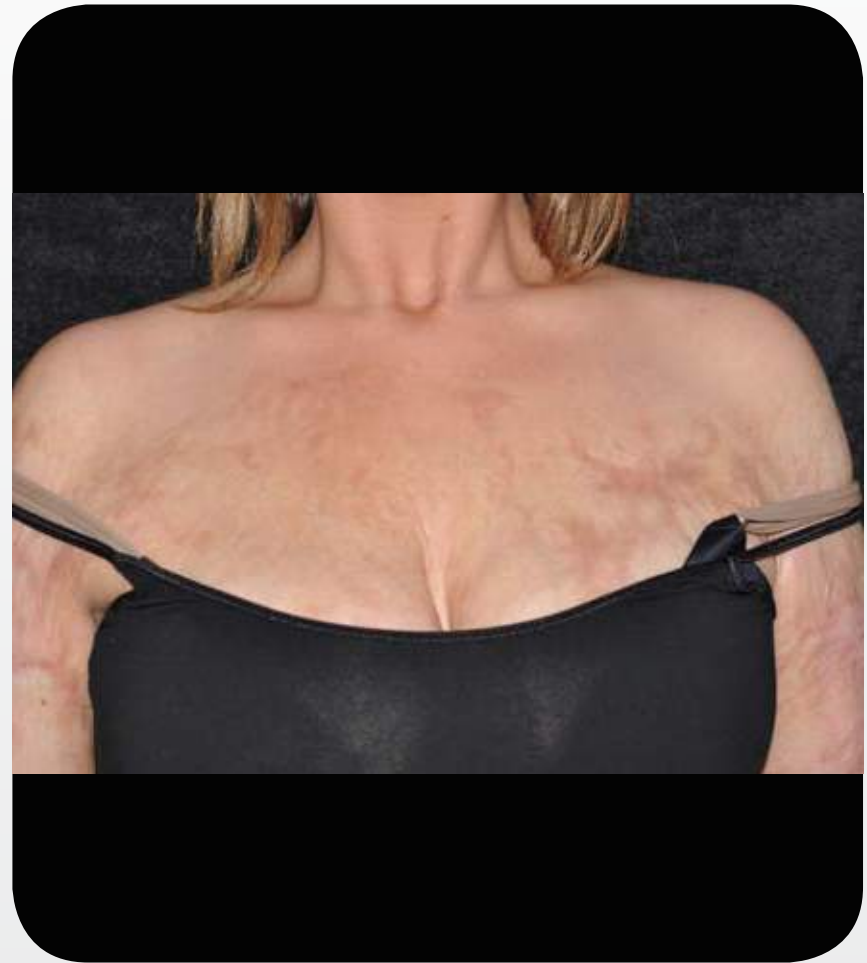

After treatment

Scar Revision The Berns Triplets; Chandra, Trae & Jordan



Baseline

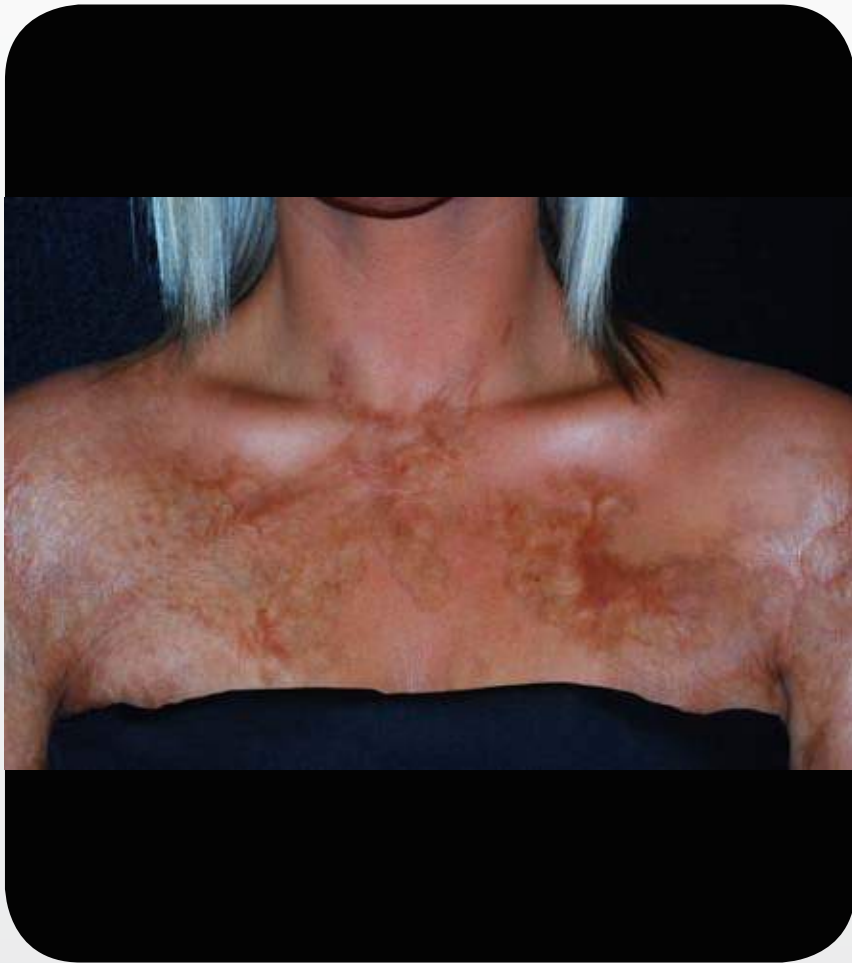

After treatment

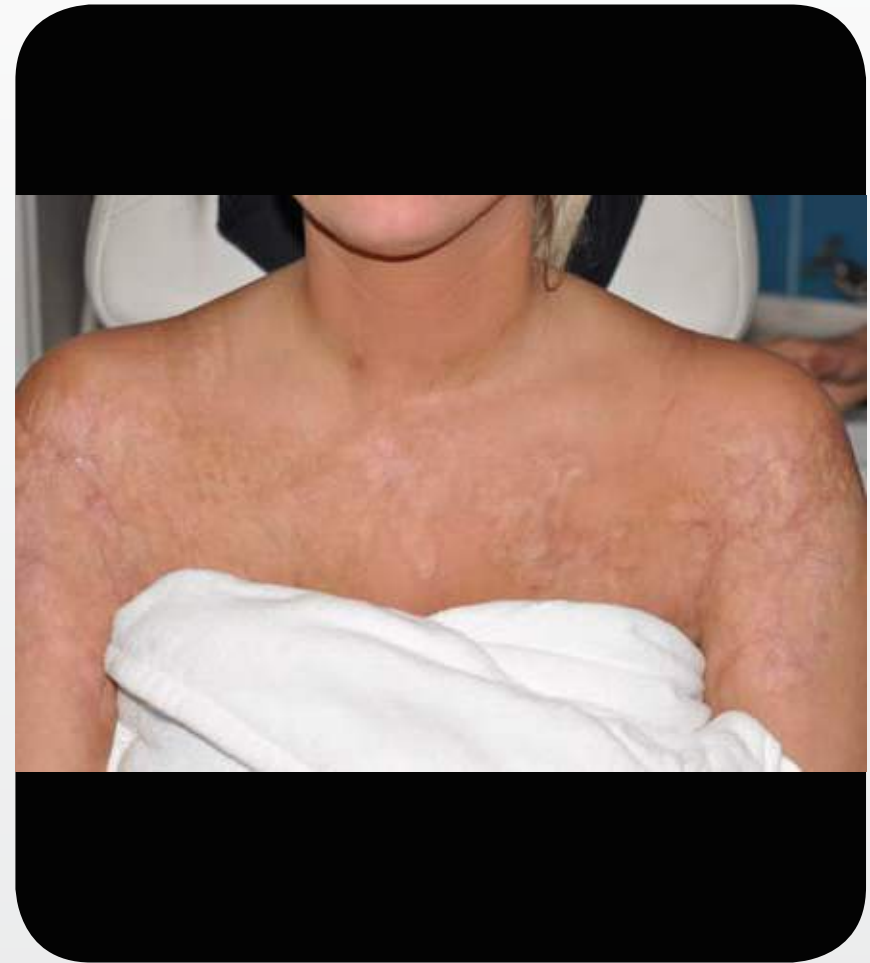
Courtesy of Jill S. Waibel, MD

PB-1003880 Rev C

Scar Revision The Berns Triplets; Chandra, Trae & Jordan



Baseline

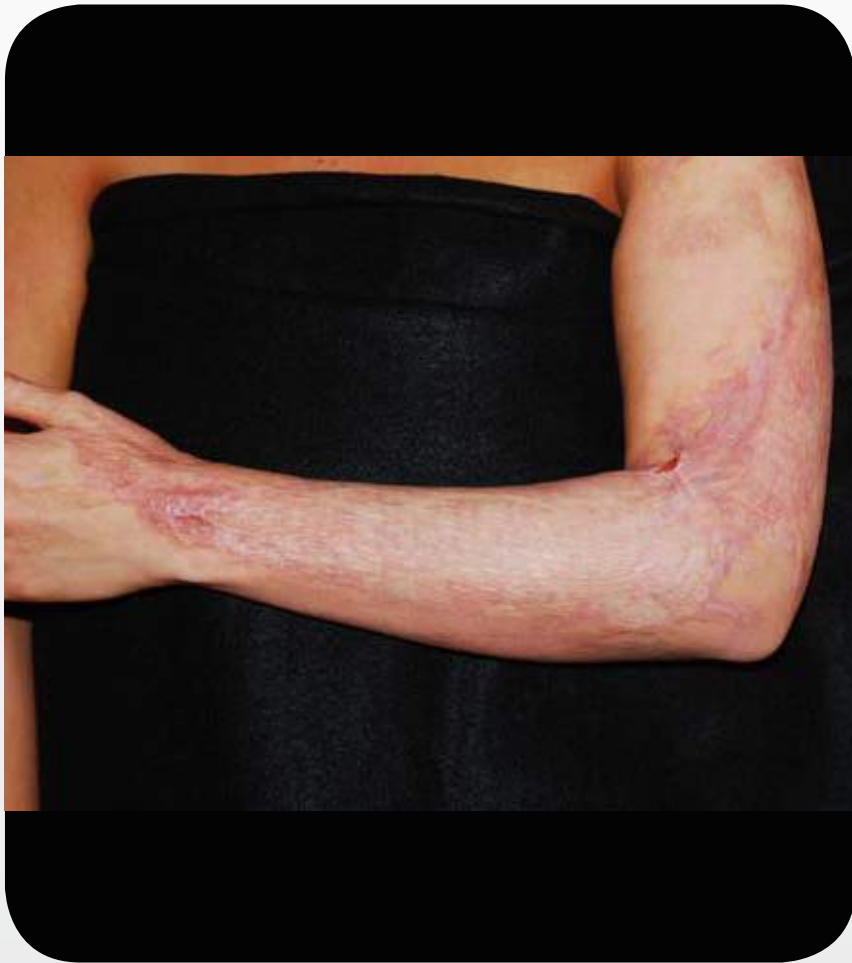

After treatment

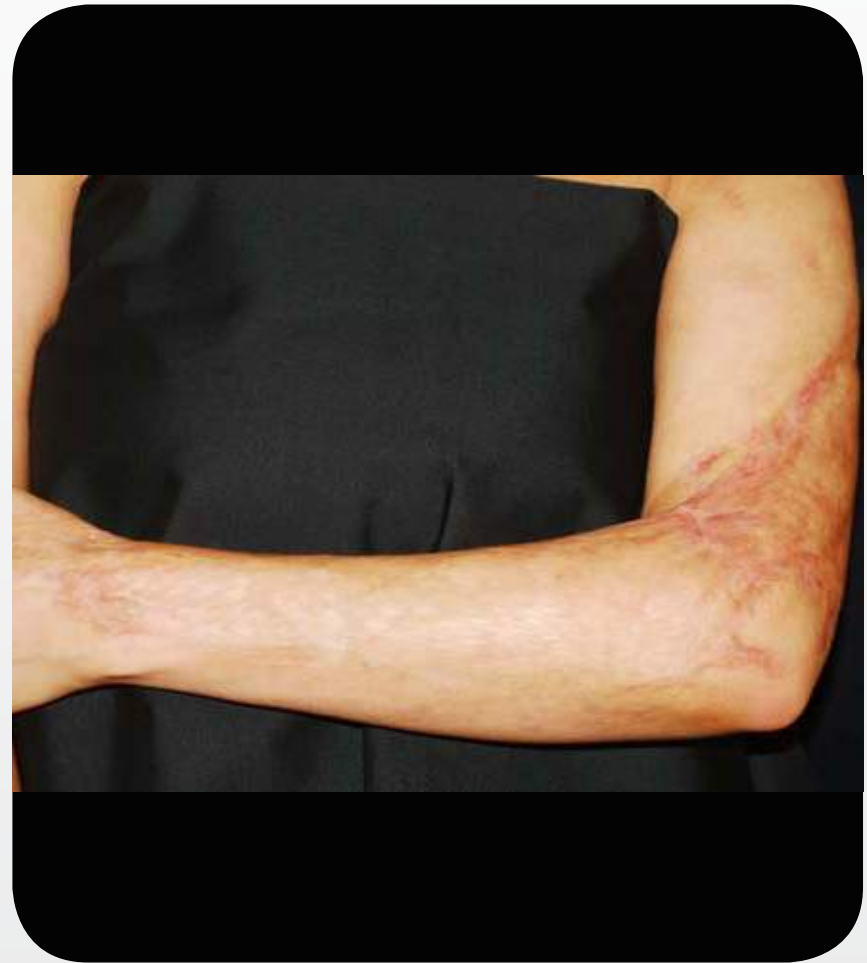Courtesy of Jill S. Waibel, MD

PB-1003880 Rev C

Scar Revision The Berns Triplets; Chandra, Trae & Jordan



Baseline

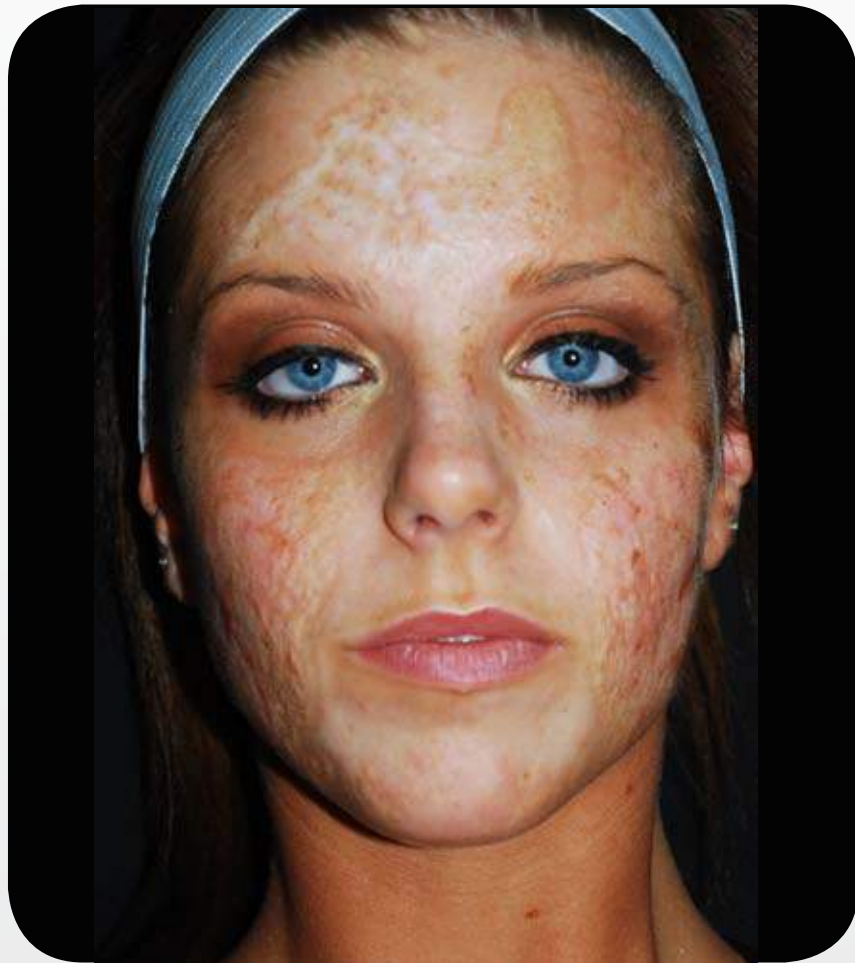

After treatment

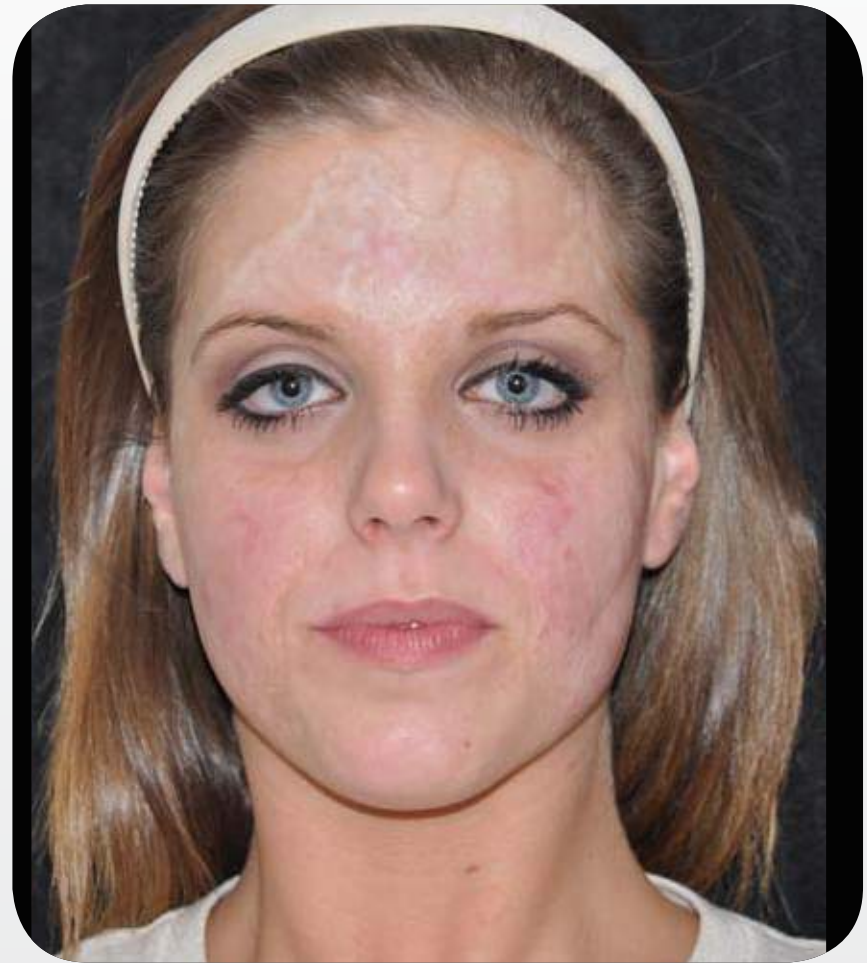
Courtesy of Jill S. Waibel, MD

PB-1003880 Rev C

Scar Revision The Berns Triplets; Chandra, Trae & Jordan



Baseline




After treatment

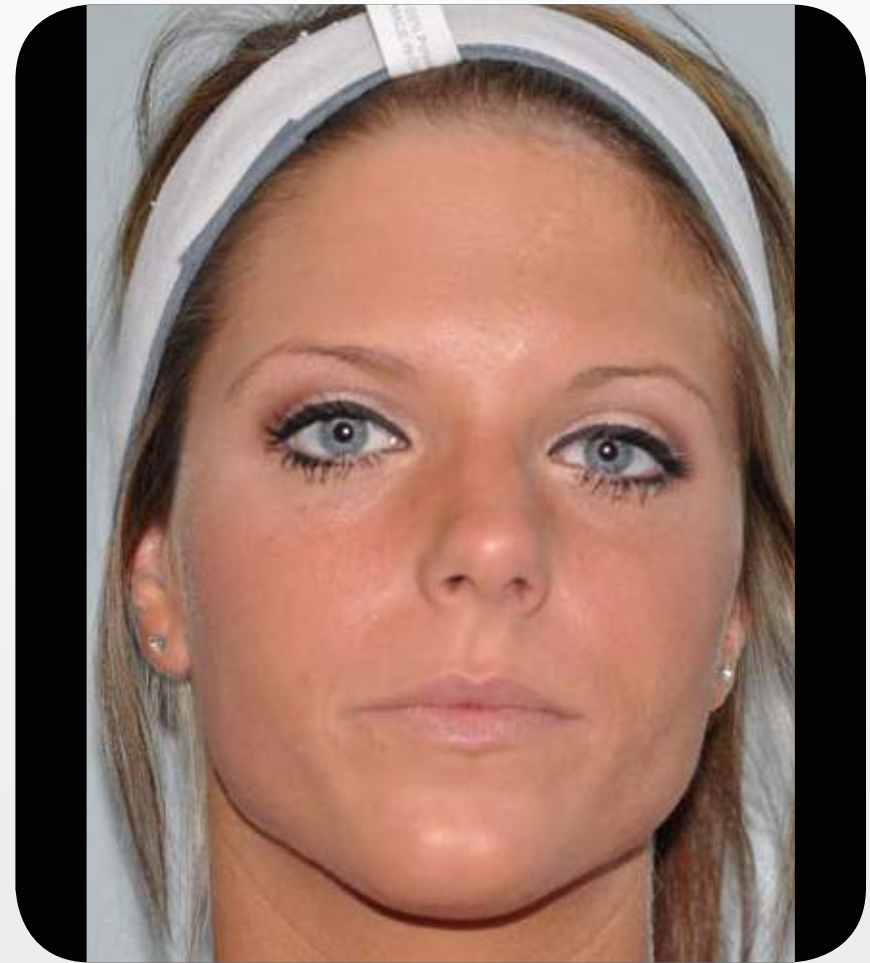
Courtesy of Jill S. Waibel, MD

PB-1003880 Rev C

Scar Revision The Berns Triplets; Chandra, Trae & Jordan



Baseline

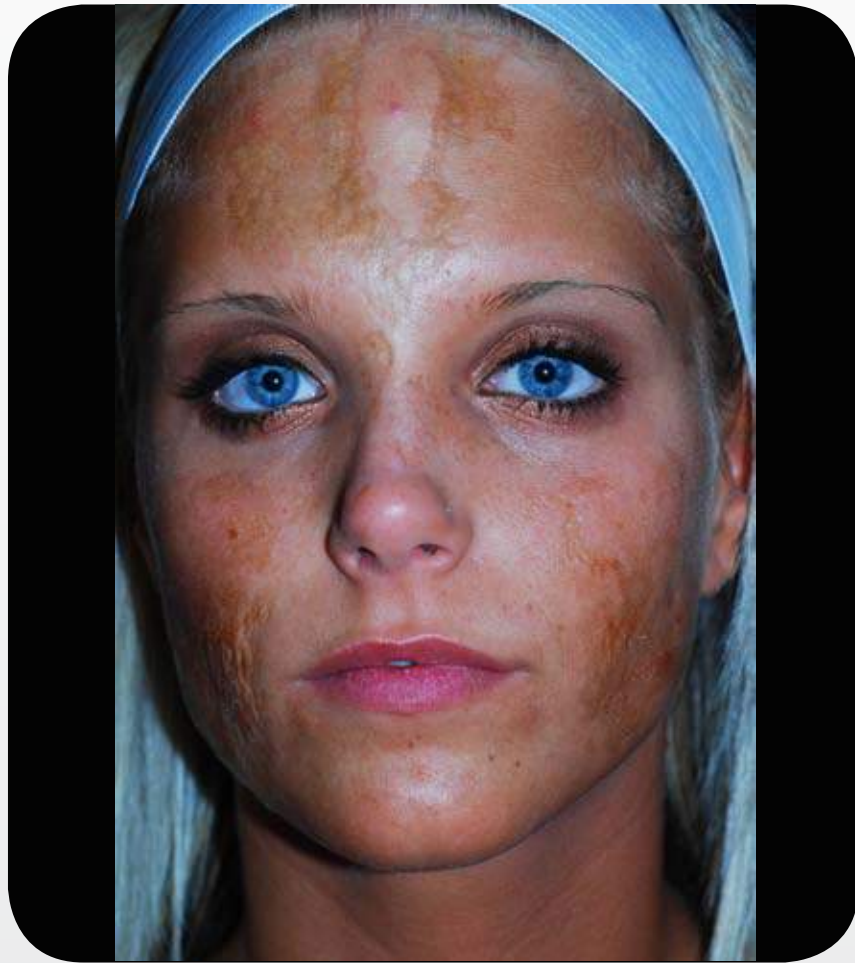

After treatment

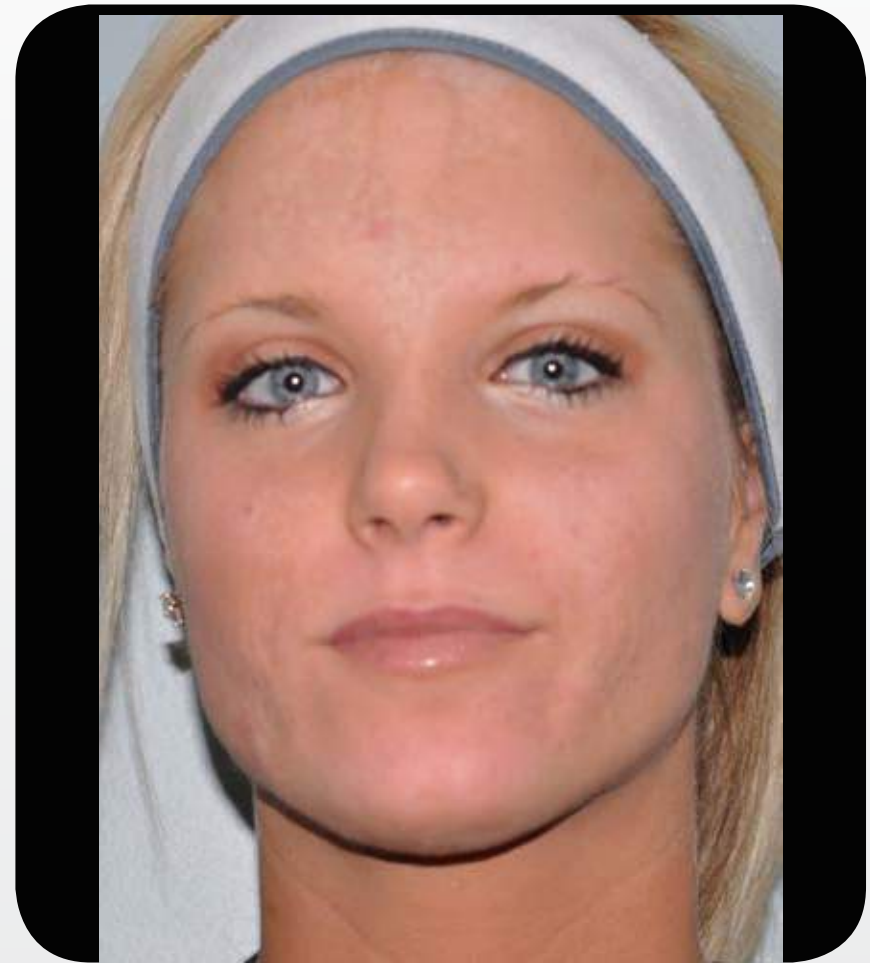
Courtesy of Jill S. Waibel, MD

PB-1003880 Rev C

Scar Revision The Berns Triplets; Chandra, Trae & Jordan



Baseline

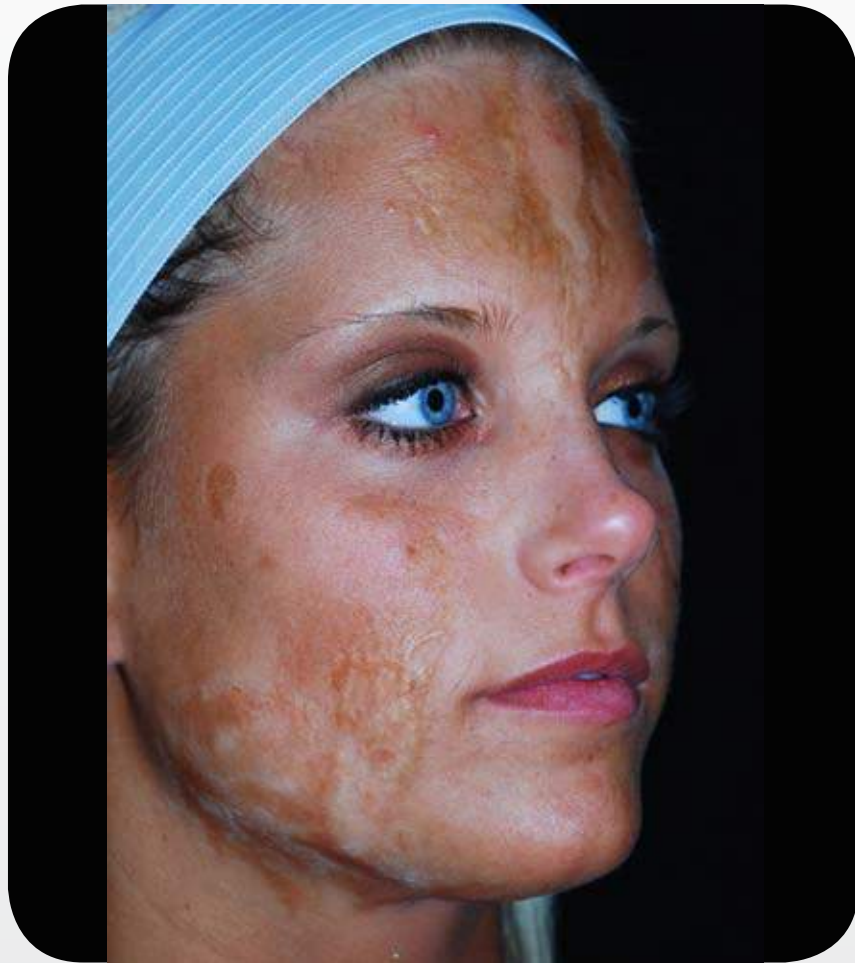

After treatment

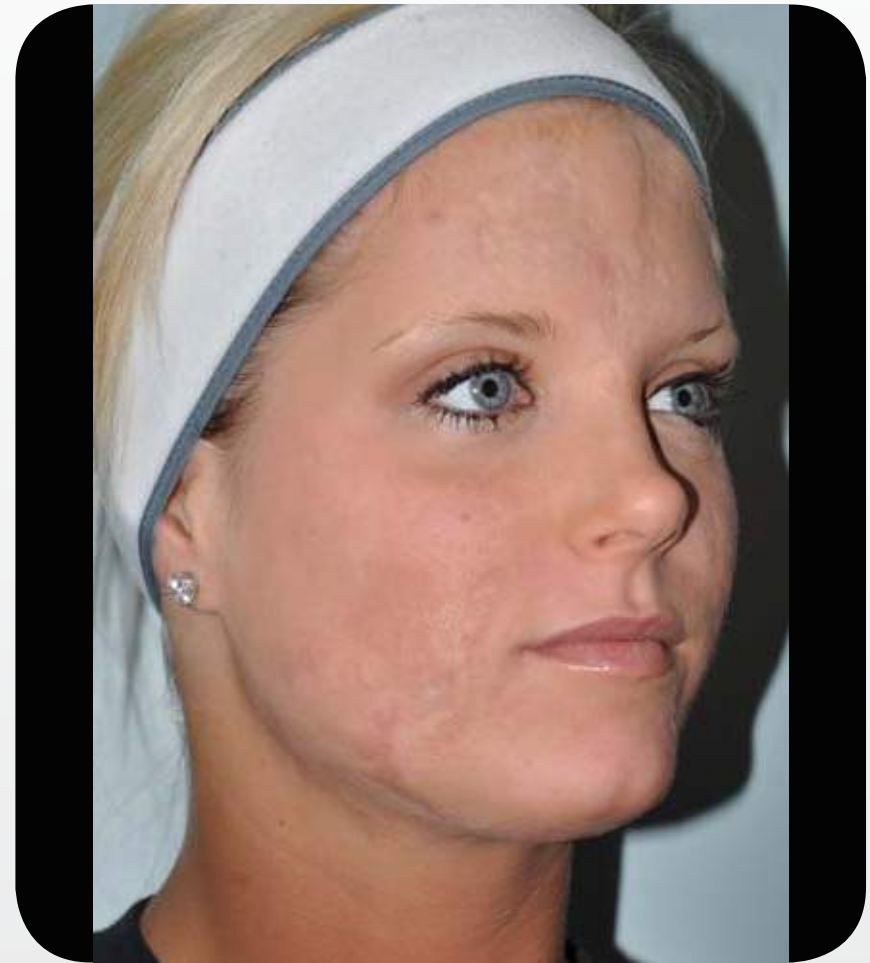Courtesy of Jill S. Waibel, MD

PB-1003880 Rev C

Scar Revision The Berns Triplets; Chandra, Trae & Jordan



Baseline



After treatment

Courtesy of Jill S. Waibel, MD

PB-1003880 Rev C